

Chapter 4

Inner Ear Malformations

Introduction	89
Embryology	89
History of Classifications	90
Sennaroglu Classification	90
Sawai Man Singh Classification	110
Cochlear Aperture Anomalies	117
Cochlear Nerve Anomalies	117
Internal Acoustic Canal Anomalies	124
Summary of Cochlear Malformations	127



4 Inner Ear Malformations

Introduction

With the advent of technology, cochlear implantation has become the standard treatment for patients with bilateral severe-to-profound sensorineural hearing loss. Suitable candidates provide us with gratifying results; however, when a patient has poor results, it can be upsetting for the patient and the surgeon. Cochleovestibular malformation is one preoperative predictor of outcome. Inner ear malformations are found in 10 to 30% of patients with congenital sensorineural deafness on high-resolution computed tomography (HRCT) of the temporal bone^{1,2} made possible with advances in imaging. Identifying these malformations is important preoperatively as it has a significant impact on surgical technique, electrode array choice, surgical complications, and cochlear implantation results.³ Therefore, proper consent is also needed.

Embryology

Knowledge regarding the embryogenesis of the inner ear is important to understand the development of various inner ear malformations. During the third week of gestation, there is thickening of the surface ectoderm on either side of the rhombencephalon, resulting in an otic placode. The otic placode invaginates to form an otic pit. Around fourth week the otic pit closes off to form an otocyst. During the fifth week, the labyrinth is well-differentiated into vestibular and cochlear pouches. Vestibular portion forms first which is followed by the cochlear portion development. By sixth week, the anterior pouch of labyrinth elongates to form the cochlea. Cochlea attains adult size by 10 weeks of gestation. Differentiation of organ of Corti starts by 10th week and cochlea is fully developed by sixth month. The labyrinth is fully formed by 5 months of gestation. The ganglion cells of the vestibulocochlear nerve arise from the otic vesicle during the fourth week and all synapses both afferent and efferent are formed by the seventh fetal month. The maturation of connections between the cochlea and peripheral nerves takes place during the last trimester. The internal acoustic canal (IAC) is formed by inhibition of cartilage formation at the medial aspect of the otic vesicle. This presence of the vestibulocochlear nerve is required for this inhibition to occur. In the absence of the eighth nerve, IAC is not formed.

History of Classifications

In 1791, Carlo Mondini (1729–1803), dissected the temporal bone of an 8-year-old boy who was deaf. The child had an accident with a carriage, leading to foot infection and later gangrene. In those days, as there were no antibiotics the boy succumbed to this infection. Mondini dissected his temporal bone and identified three things, viz superior coil of the cochlea was missing, the entire labyrinth was enlarged, and the vestibular aqueduct (VA) was very large. This triad thus came to be known as Mondini's dysplasia. Sadly for the next two centuries, almost every malformation of the inner ear was labelled as Mondini's dysplasia.⁴ After renewed interest in the inner ear due to cochlear implants (CIs), various classifications for cochleovestibular malformations were put forward. The accepted ones include those of Jackler et al (1987),¹ Phelps et al (1992),⁵ Sennaroglu et al (2002),⁶ and Grover et al (2019).⁷ Prior to these classifications, almost all malformations were labelled as Mondini's dysplasia. Jackler et al outlined the terms used for malformations as: complete labyrinthine aplasia (CLA), cochlear aplasia (CA), cochlear hypoplasia (CH), incomplete partition (IP), and common cavity (CC). However, as there was no detailed description of the terms and as it was based on the development of the inner ear, the clinical significance of this classification gradually declined. Other classifications could not gain much popularity till, in 2002, Sennaroglu came out with a classification and presently this is the most well accepted classification world over. However authors believe that it is too complex and tough to follow and therefore lacks uniformity. It is not easy for the user to follow and does not predict the prognosis and complications in a graded manner. For these reasons, the authors believe that the Sawai Man Singh (SMS) classification is more practical and will be discussed in detail later. However, the reader should remember that at present, the classification given by Sennaroglu is the most accepted one worldwide.

Sennaroglu Classification

Sennaroglu came out with multiple papers regarding classification of inner ear malformations.^{3,6,8,9,10,11} He has explained the various terminologies used in these malformations in detail, including their histopathology and development. Authors would be discussing each one of them separately in this chapter.

Enlarged Vestibular Aqueduct

One of the most common inner ear malformations is enlarged vestibular aqueduct (EVA). We read in the previous chapter how to identify a normal VA (**Figs. 4.1** and **4.2**). VA is a bony structure which contains the endolymphatic duct which connects the inner ear to the endolymphatic sac in the posterior cranial fossa.

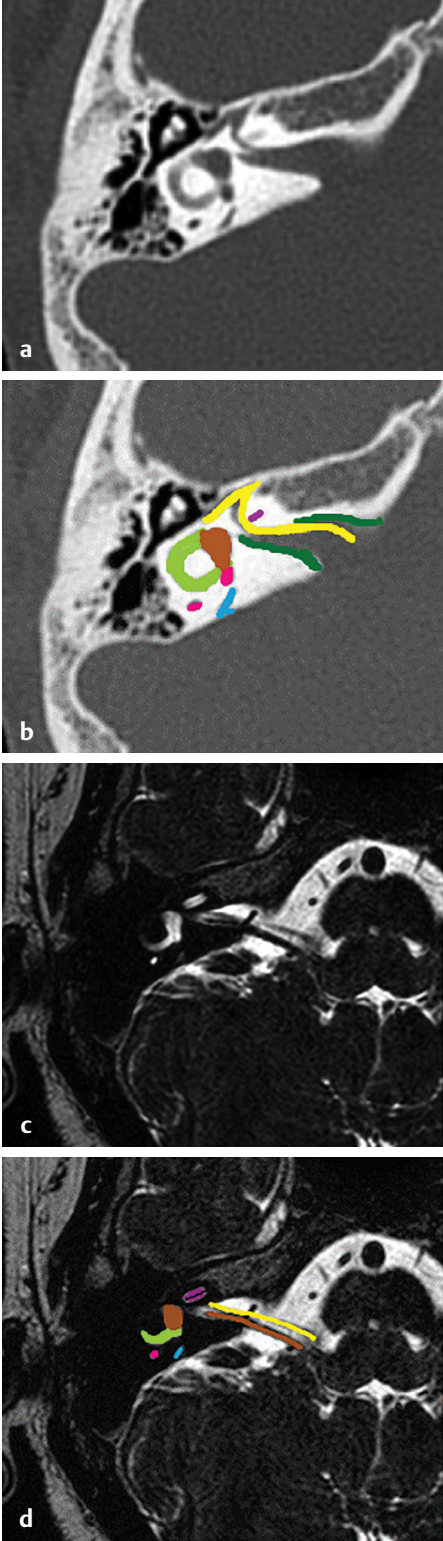


Fig. 4.1 (a, b) HRCT temporal bone, axial section, bone window and (c, d) MRI CISS/FIESTA sequence, axial section show (pink) posterior semicircular canal (SCC), (yellow) meatal and labyrinthine segment of facial nerve, (dark pink) middle turn of cochlea, (brown) vestibule and superior vestibular nerve, (light green) lateral SCC, (blue) vestibular aqueduct, and (dark green) IAC.

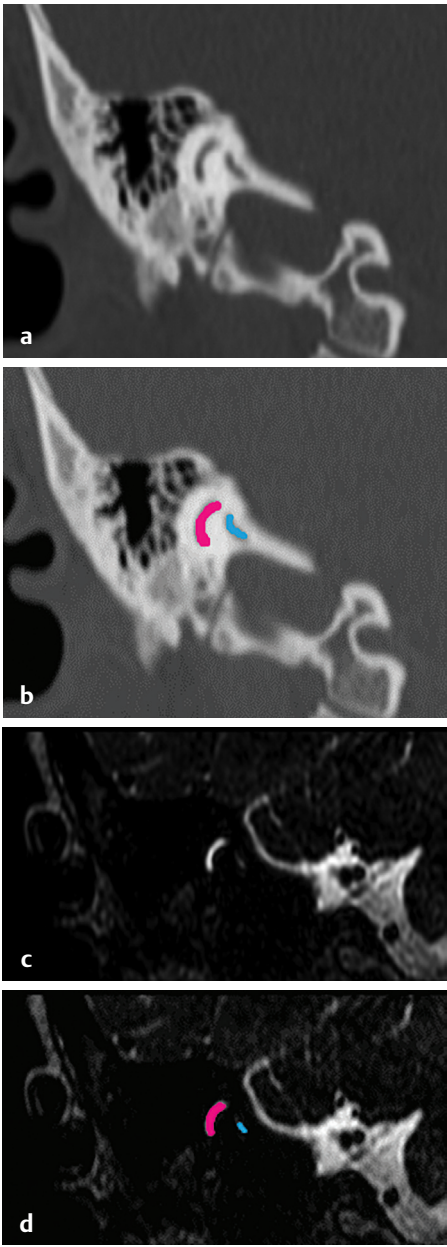


Fig. 4.2 (a, b) HRCT temporal bone, coronal section, bone window and (c, d) MRI CISS/FIESTA sequence show (pink) posterior semicircular canal, (blue) vestibular aqueduct.

Various criteria have been stated for EVA (**Fig. 4.3**); the most common ones which gained acceptance are Valvassori and Clemis criteria, Cincinnati criteria, and Wilson criteria.

1. Valvassori and Clemis criteria (1978): This is the most accepted criteria for the diagnosis of EVA. According to this VA is said to be enlarged if the width measured at the midpoint of its course from the vestibule to the opening (operculum) in the posterior cranial fossa is more than 1.5 mm¹² (**Fig. 4.4**).
2. Cincinnati criteria: In 2007, Boston et al suggested the Cincinnati criteria.¹³ They stated that VA is to be considered enlarged if the width measured at the midpoint is greater than 0.9 mm or at the operculum is greater than 1.9 mm.
3. Wilson criteria: Urman and Talbot defined EVA as any segment of the VA twice that of the adjacent posterior semicircular canal (SCC).¹⁴

EVA can be a sign of a genetic disorder called Pendred syndrome, a cause of childhood hearing loss. Hearing loss associated with Pendred syndrome is usually progressive, which means that a child will lose hearing over time. Another feature of Pendred syndrome is goiter.

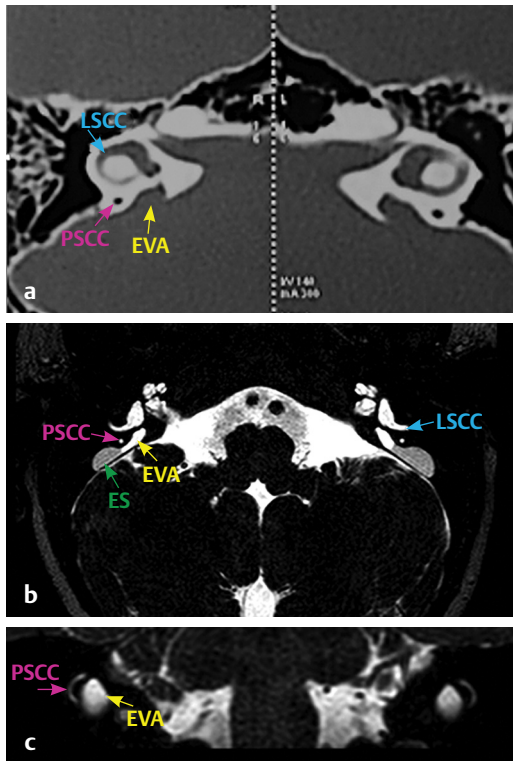


Fig. 4.3 (a) HRCT temporal bone, axial section bone window and (b, c) MRI CISS sequence, axial and coronal sections show PSCC (pink arrow), LSCC (blue arrow), endolymphatic sac (ES, green arrow) and enlarged vestibular aqueduct (EVA, yellow arrow).

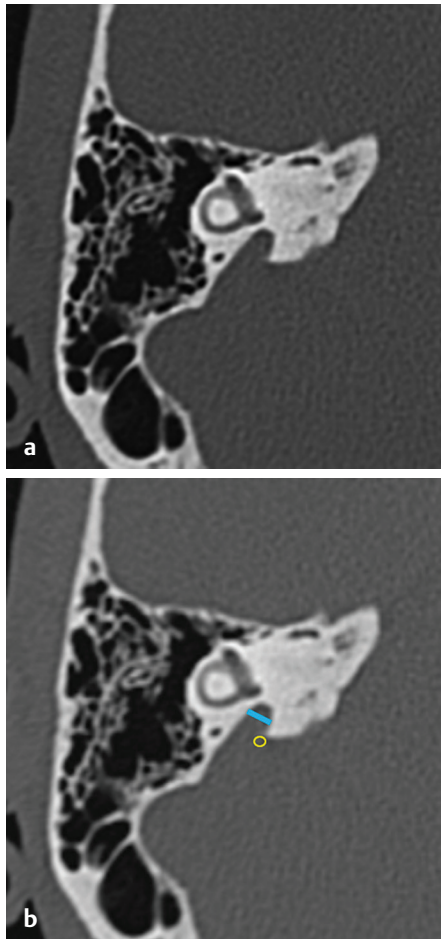


Fig. 4.4 (a, b) HRCT temporal bone, axial section, bone window showing measurement of the width of vestibular aqueduct at the midpoint (blue line) and at operculum (yellow O).

EVA has many causes, not all of which are fully understood. The most well-known cause of EVA and hearing loss is mutations in a gene called *SLC26A4* (previously known as the *PDS* gene). Two mutations in the *SLC26A4* gene can result in Pendred syndrome.

There are two major hypotheses for hearing loss in EVA. The first hypothesis was based on pressure transmission. Repeated minor head trauma could lead to progressive hearing loss due to transmission of the pressure change to the inner ear.¹⁵ This was also proven radiologically by Sennaroglu in a case report where he showed dilatation of scala vestibuli alone in a case of EVA in magnetic resonance imaging (MRI) thereby strengthening the hypothesis that pressure transmission from EVA led to this dilatation.¹⁶ However, the majority of recent literature supports the hypothesis that EVA is like a marker to genetic mutation in the *SLC26A4* gene, and the mutation itself is responsible for hearing loss. Grover wrote a letter to the editor in the same respect.¹⁷

Complete Labyrinthine Aplasia

CLA is also known as Michel deformity. It indicates the absence of any labyrinthine structure. This happens when developmental arrest happens before the formation of otocyst. This is an absolute contraindication for CIs and patients with CLA need auditory brainstem implants. Based on radiological findings, Sennaroglu divided CLA into three types.

CLA with Petrous Bone Aplasia or Hypoplasia

This is seen when CLA is accompanied with absent or minimally developed petrous bone. In such a condition, many times dura may be seen adjacent to the middle ear (Fig. 4.5).

CLA without Otic Capsule

In this condition, the inner ear structures are absent however the petrous bone is normally developed (Fig. 4.6).

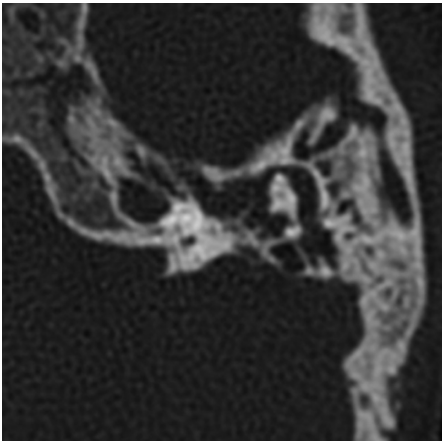


Fig. 4.5 HRCT temporal bone, axial sections, bone window shows CLA with aplastic or hypoplastic petrous bone thereby no inner ear structures are visualized and dura is seen right next to the middle ear.

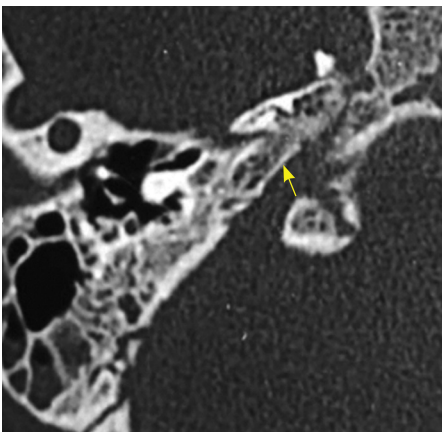


Fig. 4.6 HRCT temporal bone, axial section, bone window shows CLA without otic capsule with presence of petrous bone (yellow arrow).

CLA with Otic Capsule

In this case, the inner ear is completely absent however the otic capsule is developed and therefore we can see the facial nerve running a normal course (Fig. 4.7).

Rudimentary Otocyst/Primitive Otocyst (Michel's Otocyst Deformity)

A rudimentary otocyst (RO) (Fig. 4.8) is defined as an incomplete millimetric representation of the otic capsule (round or ovoid in shape) without an IAC.³ The RO occurs due to the developmental arrest between the third and fourth weeks of inner ear embryogenesis. This insult usually occurs at the beginning of the formation of the otocyst. Occasionally, RO can be accompanied by rudimentary SCC formations. RO represents an anomaly between CLA (where there is no inner development) and CC. RO is a very small cystic structure without the formation of IAC. The only option of hearing rehabilitation in RO is by auditory brainstem implants.

Cochlear Aplasia

Important features of CA include:

1. Absence of cochlea.
2. The labyrinthine segment of the facial nerve is displaced anteriorly and occupies the normal location of the cochlea.
3. Vestibule and SCCs occupy their normal anatomic location in the posterolateral part of the fundus of the IAC.
4. The cochlear nerve is absent.

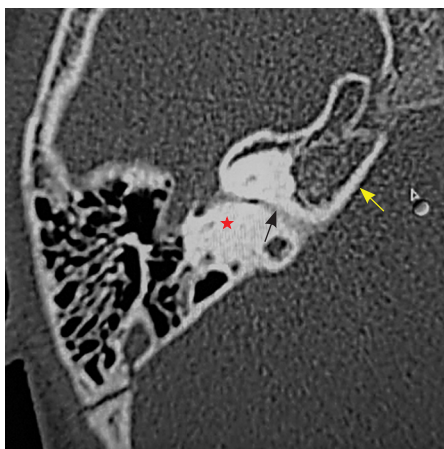


Fig. 4.7 HRCT temporal bone, axial section bone window shows CLA with otic capsule (red star, otic capsule; yellow arrow, petrous bone; black arrow, facial nerve).

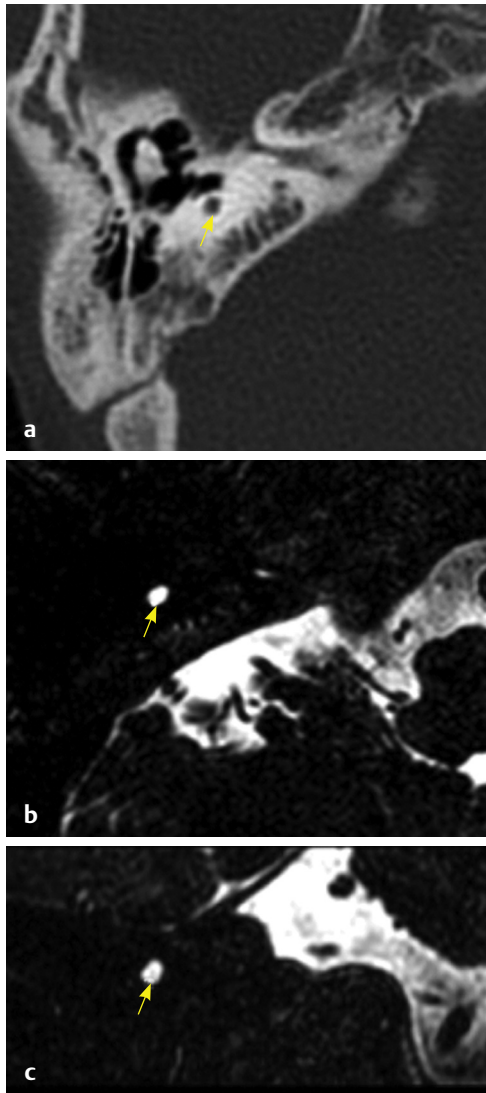


Fig. 4.8 (a) HRCT temporal bone, axial section bone window and (b) axial section and (c) coronal sections on MRI, CISS sequence show RO (yellow arrow) without internal acoustic canal.

Based on these, if the vestibular system is dilated or not, CA is divided into: (A) CA with normal labyrinth and (B) CA with a dilated vestibule (CADV).

1. CA with normal labyrinth (**Fig. 4.9**):
In this anomaly there is:
 - Absence of cochlea, and
 - Normally developed vestibule and SCCs.
2. CA with a dilated vestibule (CADV) (**Fig. 4.10**):
In this anomaly there is:
 - Absence of cochlea, and
 - Dilated vestibule and SCCs.

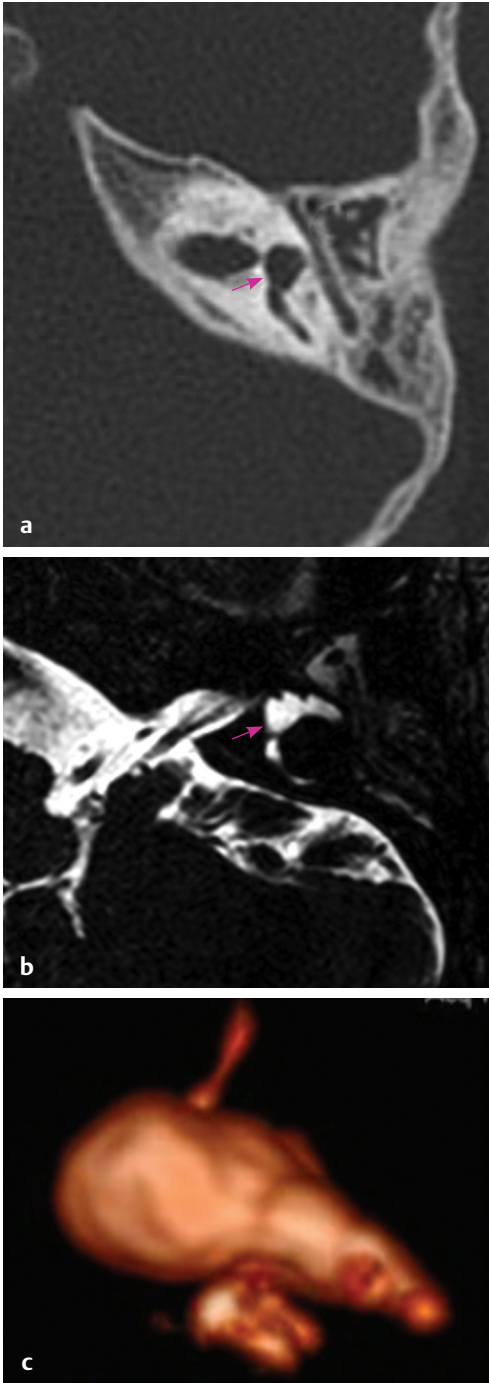


Fig. 4.9 (a) HRCT temporal bone, bone window and (b) MRI CISS sequence, axial section shows normal vestibule (pink arrow) and absent cochlea (c) 3D reconstructed image showing cochlear aplasia.

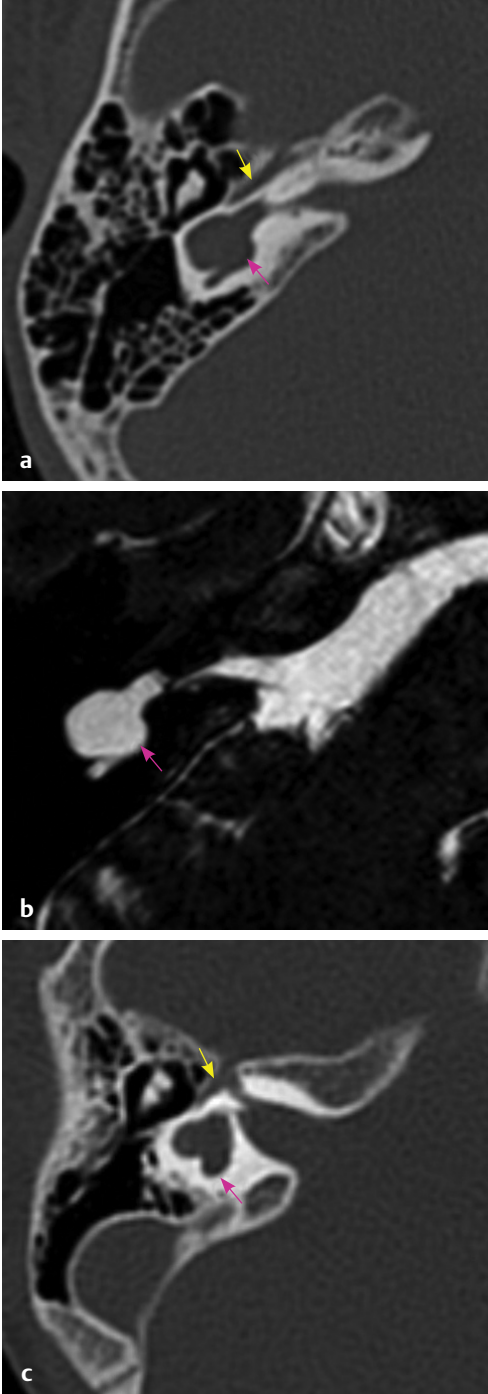


Fig. 4.10 (a, c) HRCT temporal bone, bone window and (b) MRI CISS sequence, axial section shows dilated vestibule (pink arrow) with anteriorly displaced facial nerve (yellow arrow) and absent cochlea.

Table 4.1 Differences between CADV and CC

Features	CADV	CC
Cochlea	Absent	The cochlear component present anterior to IAC
Vestibule	Dilated and located posterolateral to IAC	The vestibular component present posterior to IAC
IAC	Enters into the anterior-most part of the cavity	Enters into the center of the cavity
Cochlear nerve on 3T MRI (Stenver's projection)	Absent	Cochleovestibular nerve complex present, occasionally cochlear nerve may be seen separately
Behavioral audiometry	Response is absent	Responses present
Cochlear implantation	Contraindicated and ABI is an option for hearing rehabilitation	Option for hearing rehabilitation

Abbreviations: ABI, Auditory brainstem implant; CADV, cochlear aplasia with a dilated vestibule; CC, common cavity; IAC, internal auditory canal, MRI, magnetic resonance imaging.

It is important to differentiate between CADV and CC malformation radiologically prior to CI, as an attempt of CI in CADV patients where there is an absence of cochlea and cochlear nerve may result in no hearing benefit to the patient after surgery. The difference between CADV and CC malformation is enumerated in **Table 4.1**.

Common Cavity

The CC malformation was first described by Edward Cock in 1838. CC occurs as a result of developmental arrest during the fourth and fifth week of gestation¹⁸ when the differentiation of inner ear structures into cochlea and vestibule occurs.

Important features of CC are:

1. It is defined as a single, large, ovoid or round structure, representing cochlea and vestibule (**Fig. 4.11**).
2. This cavity contains neural elements of both cochlea and vestibule.
3. Rudimentary parts of the SCC can be present.
4. The IAC is well developed and enters the midportion (center) of the cavity.
5. In most of the cases, a common cochleovestibular nerve (CVN) is present and occasionally a separate cochlear nerve may also be seen.
6. CI is an effective treatment option for hearing in CC; however, the hearing performance depends on the number of cochlear nerve fibers present in the cochleovestibular bundle which can be evaluated by behavioral audiometry responses.

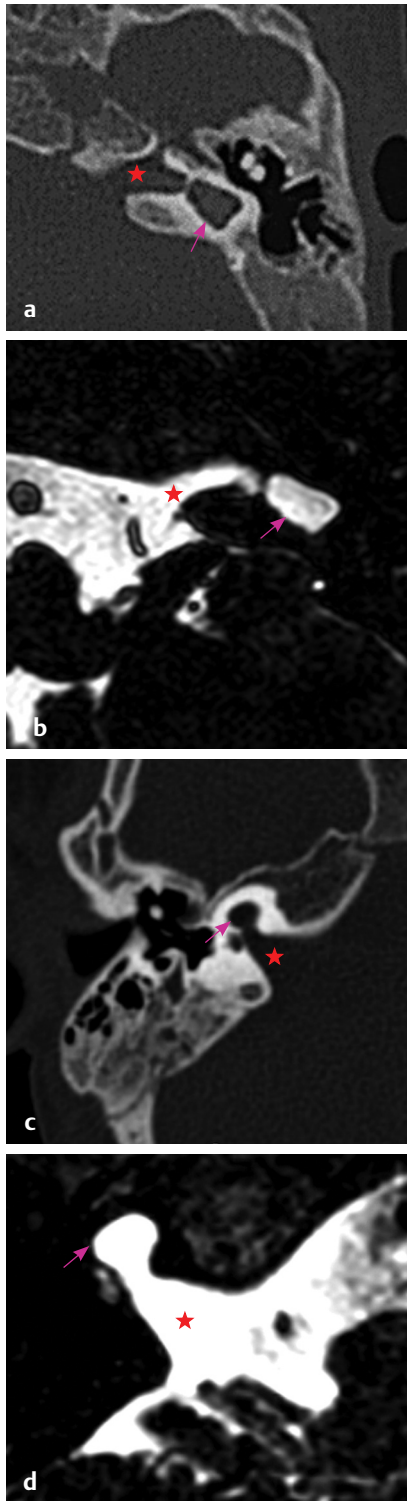


Fig. 4.11 (a, c) HRCT temporal bone, bone window and (b, d) MRI CISS sequence, axial section shows internal acoustic canal (red star) entering the common cavity (pink arrow) in the center.

7. The surgical approach for CI is via a transmastoid banana-shaped labyrinthotomy which was first described by McElveen et al.¹⁹
8. As the neural elements are mainly located at the periphery of the cavity, straight electrodes are preferred. Precurved modiolar hugging and half banded electrodes need to be avoided in such cases.
9. The length of the electrode array required can be calculated prior to surgery by using the formula $2\pi r$, where r is the radius of CC.

A recent study by Nora et al²⁰ mentions the use of 3D reformation images to differentiate between CADV and CC, as routine HRCT and MRI may underestimate the malformation, especially when the resolution is poor. In this study, a line was drawn along the longitudinal axis of the IAC and another along the medial border of the vestibular part of the inner ear extended along the posterior limit of the IAC as shown in **Fig. 4.12**. The cochlear portion of the cavity was considered present if the CC was located anterior and was said to be absent if the CC was present only posterior to the IAC.

Cochlear Hypoplasias

CH by definition has smaller external dimensions, length as well as height, so the cochlear duct length is less than 25 mm. These are the most interesting malformations because they present in various ways. Hearing may be normal or there may be profound loss; conductive, sensorineural, or mixed hearing loss. Patients with pure conductive hearing loss (specially those with CH3 and CH4) may benefit from stapes surgery. Cochlear nerve deficiency is frequent in CH. As the cochlea is hypoplastic, the promontory is flat and many times the round window is not that well visualized. Facial nerve may also be running an anomalous course. As the turns are smaller and narrower, it is better to use smaller and slimmer electrodes. In his latest modifications to the classification, Sennaroglu has divided CH into four types.

Cochlear Hypoplasia Type 1 (CH1) (Bud-like Cochlea)

Cochlea is visualized like a small bud, arising from the IAC. No modiulus and interscalar septa are identified (**Fig. 4.13**).

Cochlear Hypoplasia Type 2 (CH2)

It is also known as cystic hypoplastic cochlea. Important features of CH2 include (**Fig. 4.14**):

1. Absent modiulus.
2. Absent interscalar septa.
3. Vestibule and VA may be enlarged.
4. There might be a defect between IAC and cochlea, leading to higher chances of cerebrospinal fluid (CSF) gusher during surgery.

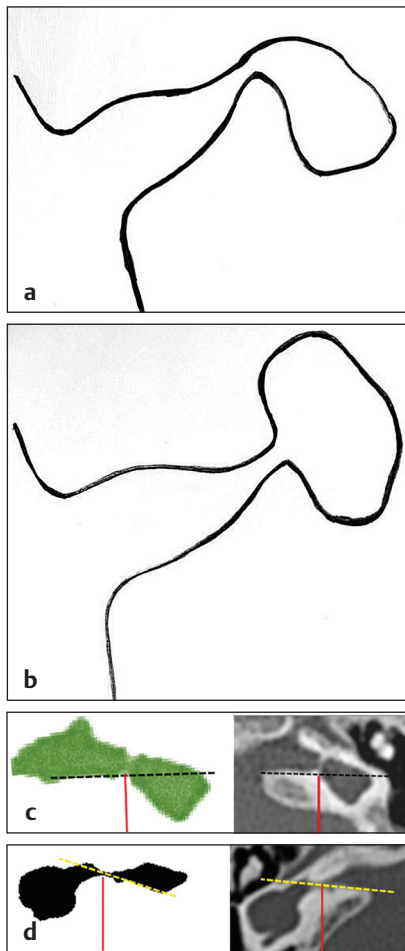


Fig. 4.12 Difference between CADV and CC, **(a)** line diagram of CADV, **(b)** line diagram of CC, **(c)** 3D reconstruction image with cochlear portion present anterior to the longitudinal axis of IAC, and **(d)** 3D reconstruction image with cochlear portion absent anterior to the longitudinal axis of IAC.

5. Stapedial footplate defect may be present leading to CSF otorrhea and recurrent meningitis.
6. As there is no modiolus, the nerve endings are along the periphery of the cochlea. Therefore the best electrodes to be used here would be full banded lateral wall electrodes.
7. In view of chances of CSF gusher, the surgeon should be prepared for dealing with it. Some of the things include: bigger cochleostomy, let the CSF drain out before insertion of electrode array, FORM electrode (proximal part of array having a conical stopper), good sealing of the cochleostomy by tissues, be prepared to use tissue glue and lumbar drain and in worst cases subtotal petrosectomy may be needed.
8. These features are similar to IP1, however the major difference is that cochlea is smaller than 25 mm in CH2.

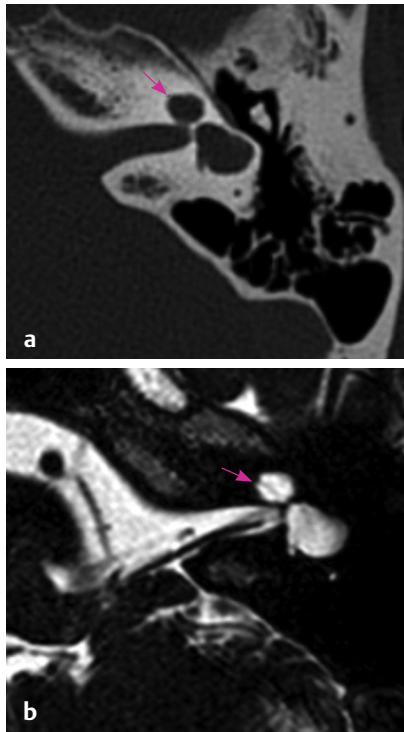


Fig. 4.13 (a) HRCT temporal bone, bone window and (b) MRI CISS sequence, axial section shows a small bud-like cochlea (pink arrow) in CH1.

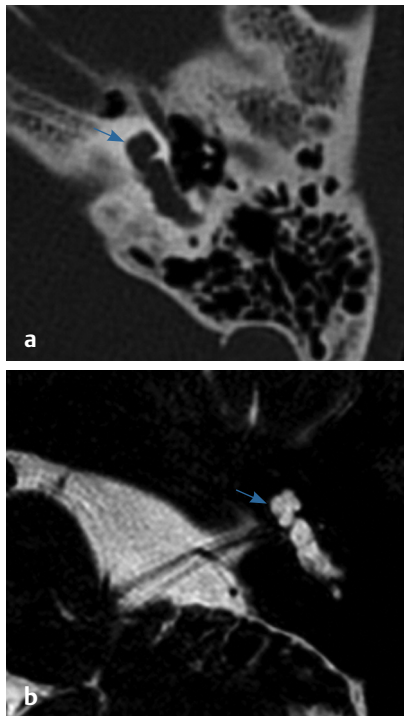


Fig. 4.14 (a) HRCT temporal bone, bone window and (b) MRI CISS sequence, axial section shows small cystic cochlea (blue arrow) with normal external outline with absent modiolus and interscalar septa.

Cochlear Hypoplasia Type 3 (CH3)

Its important features include (Fig. 4.15):

1. Fewer number of turns.
2. Shorter modiolus.
3. Shorter interscalar septa.
4. It looks like a normal cochlea, but is shorter and with fewer turns.

Cochlear Hypoplasia Type 4 (CH4)

Features of CH4 are (Fig. 4.16):

1. Normal basal turn.
2. Middle and apical turns are hypoplastic and located anteriorly.
3. Facial nerve runs an anomalous course.

Incomplete Partitions

These comprise a group of cochlear anomalies where the differentiation between the cochlea and the vestibule is clear cut. The differentiating feature from CHs is that in IP the cochlea is of normal length, that is, more than 25 mm. These are divided into three types on the basis of modiolus and inter scalar septum (Table 4.2).

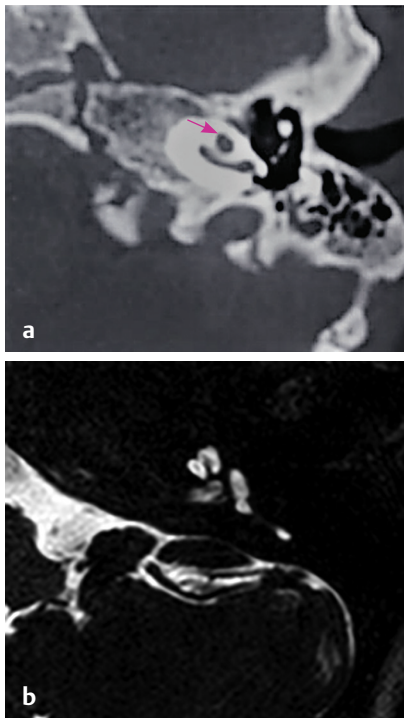


Fig. 4.15 (a) HRCT temporal bone, bone window and pink arrow points towards fewer number of turns of cochlea. (b) MRI CISS sequence, axial section shows CH3.

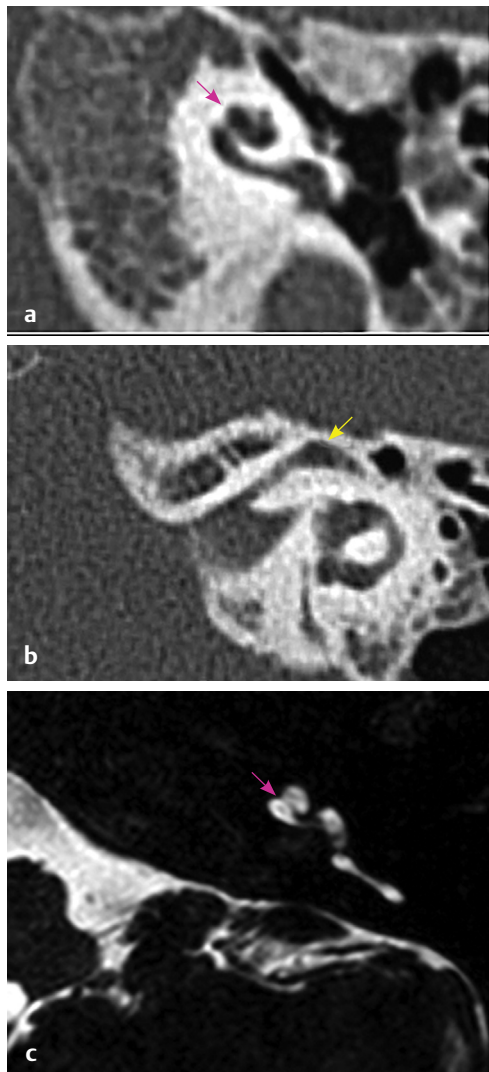


Fig. 4.16 (a, b) HRCT temporal bone, bone window, axial section shows and facial nerve (yellow arrow) is seen running an abnormal course in labyrinthine segment. (c) MRI CISS sequence, axial sections show CH4 in which cochlea (pink arrow) has hypoplastic and anteriorly placed middle and apical turns with normal basal turn and an anteriorly placed facial nerve.

Table 4.2 Differences between IP 1, 2, and 3

Deformity	Modiolus	Interscalar septa
IP1	Absent	Absent
IP2	Deficient in apical part	Deficient in apical part
IP3	Absent	Present

Abbreviation: IP, incomplete partitions.

Incomplete Partition Type 1 (IP1)

Important features of IP1 (also known as cystic cochleovestibular malformation) are (Fig. 4.17):

1. Normal external architecture.
2. Absent modiolus.
3. Absent interscalar septa.

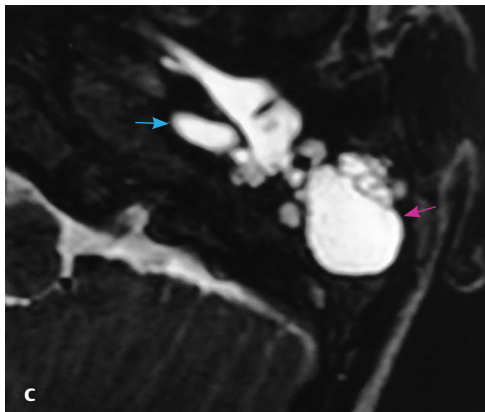
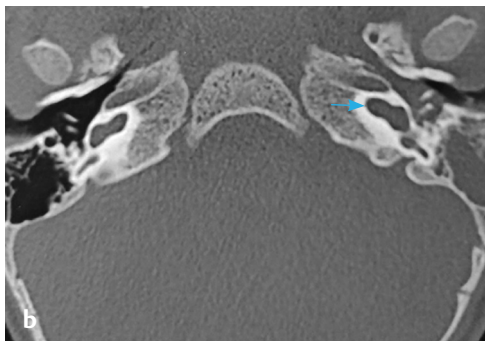
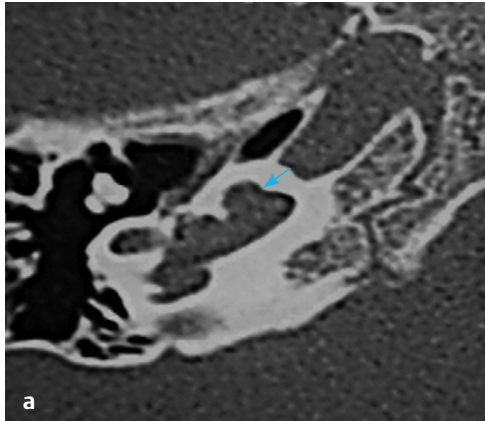


Fig. 4.17 (a, b) HRCT temporal bone, bone window and (c) MRI CISS sequence, axial sections show IP1. Cochlea (blue arrow) without modiolus and interscalar septum, and bright signal on MRI on left side indicates CSF in middle ear (pink arrow) and going into the eustachian tube.

4. Dilated vestibule.
5. There might be a defect between IAC and cochlea, leading to higher chances (approximately 50%) of CSF gusher during surgery.
6. Stapedial footplate defect may be present leading to CSF otorrhea/ otorhinorrhea and recurrent meningitis (**Fig. 4.17**).
7. As there is no modiolus, the nerve endings are along the periphery of the cochlea. Therefore the best electrodes to be used here would be full banded lateral wall electrodes.
8. In view of chances of CSF gusher, the surgeon should be prepared for dealing with it. Some of the things include: bigger cochleostomy, let the CSF drain out before insertion of electrode array, FORM electrode (proximal part of array having a conical stopper), good sealing of the cochleostomy by tissues, be prepared to use tissue glue and lumbar drain and in worst cases subtotal petrosectomy may be needed.

Incomplete Partition Type 2 (IP 2)

Important features of IP2 are (**Fig. 4.18**):

1. Apical part of the modiolus and the corresponding interscalar septa are defective.
2. Apical part of the cochlea looks cystic due to the confluence of middle and apical turns.
3. Modini's deformity: triad of IP2, EVA and dilated vestibule.
4. Hearing may be normal to profound loss (progressive loss).
5. Mild perilymph ooze may be there (no CSF gusher).
6. Any kind of electrode may be used, however complete cochlear coverage should not be an aim.

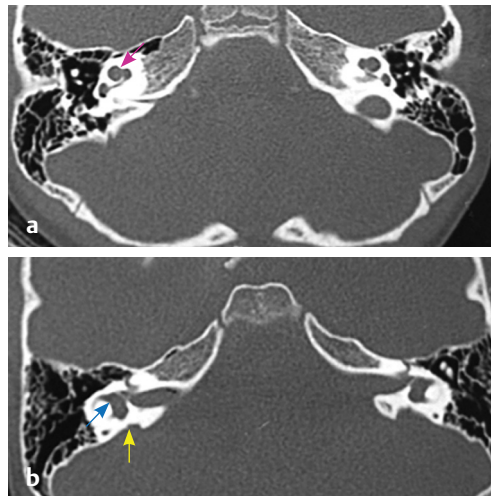


Fig. 4.18 (a, b) HRCT temporal bone, bone window, axial sections show Mondini dysplasia: IP2 - with cystic apical part of cochlea (pink arrow), dilated vestibule (blue arrow), and EVA (yellow arrow).

Incomplete Partition Type 3 (IP3)

Important features of IP3 are (**Fig. 4.19**):

1. Absent modiolus.
2. Interscalar septa present.
3. X-linked deafness.
4. There is a defect between IAC and cochlea, leading to CSF gusher during surgery (100%).
5. As there is no modiolus, the nerve endings are along the periphery of the cochlea. Therefore, the best electrodes to be used here would be full banded lateral wall electrodes.
6. Patients may present with conductive or mixed hearing loss and there have been instances when these patients have been taken up for stapes surgery. If a stapedotomy is done in such patients, intraoperative CSF gusher is encountered which then needs to be repaired and the surgery turns out to be futile. These patients invariably land up with profound SNHL requiring CI.
7. In view of 100% probability of CSF gusher, the surgeon should be prepared for dealing with it. Some of the things include: bigger cochleostomy, let the CSF drain out before insertion of electrode array, FORM electrode (proximal part of array having a conical stopper), good sealing of the cochleostomy by tissues, be prepared to use tissue glue and lumbar drain and in worst cases subtotal petrosectomy may be needed.
8. Also due to big communication between cochlea and IAC, there are chances that electrode array may get misplaced into IAC. Therefore this should be cross-checked intraoperatively with a C-arm. If it

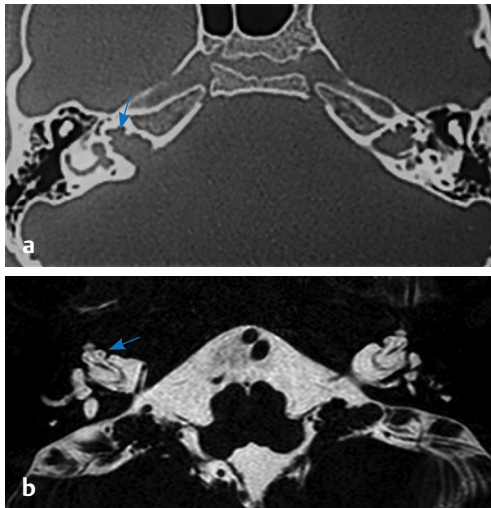


Fig. 4.19 (a) HRCT temporal bone, bone window and (b) MRI CISS sequence, axial sections show IP3 (blue arrow) - cochlea has interscalar septum without modiolus and with bilateral dilated internal acoustic canal.

is found to be so, then the electrode array should be removed and inserted again in a different direction, usually antero-superiorly. Electrode array may also be inserted with help of intraoperative fluoroscopy guidance.

9. Facial nerve anomalies may be present.

Sawai Man Singh Classification

Classifications in general, and specifically those relevant to cochleovestibular malformations (CVM), are required for a few basic reasons to make the things easier. The problem with the Sennaroglu et al classification is that overlapping or intermediate forms exist, which creates confusion. This confusion is worsened by the fact that diagnosis of CH is very subjective. There is currently no literature describing how to radiologically measure the length of a malformed cochlea. Thus, there can be overlap between various types of IP and CH. For example, it is sometimes difficult to differentiate between IP type II and CH type III, and IP type I and CH type II. Furthermore, the many additions to the definitions of these terms make it difficult for people to remember and follow this classification. This also leads to problems with uniformity, which is another reason why we need a standard classification. The complex nature of this classification makes it tough for surgeons, audiologists, and speech and language pathologists to understand. Uniformity can be lost even while communicating within the team, which leads to problems in reporting the results.

Another major reason why we need another classification is for treatment planning and predicting complications. Sennaroglu et al's classification³ can indicate this information, but in a complex manner. For example, if we were to examine various types of CH and IP, and predict which of these have a higher chance of a CSF gusher, then it would be CH type II, and IP types I and III. For any surgeon, a classification that immediately indicates that particular terminology is associated with higher chances of CSF gusher would make more sense and be easier to remember. If not one term, then at least the terms should be in a sequence and not haphazardly placed. Another major reason for a new classification is for predicting prognosis. The terms used in all classifications, be they for angiofibroma or malignancy, or any other disease, usually go from good to bad prognosis, or vice versa. However, this is not seen in this classification. For example, prognosis of IP type II is better than IP types I and III. Furthermore, it is difficult to prognosticate various types of CH and IP. In short, the present classification systems are not adequate for five major reasons. Classification should: make things easier for user, provide uniformity, enable treatment planning (including electrode selection), and allow the prediction of complications and prognosis. Thus, a new, simpler and more clinical classification, with well-delineated types and definitions, is needed.

The SMS classification of CVM⁷ took into consideration three features of cochlear anatomy, namely cochlear morphology, the modiolus, and the lamina cribrosa (**Fig. 4.20**).

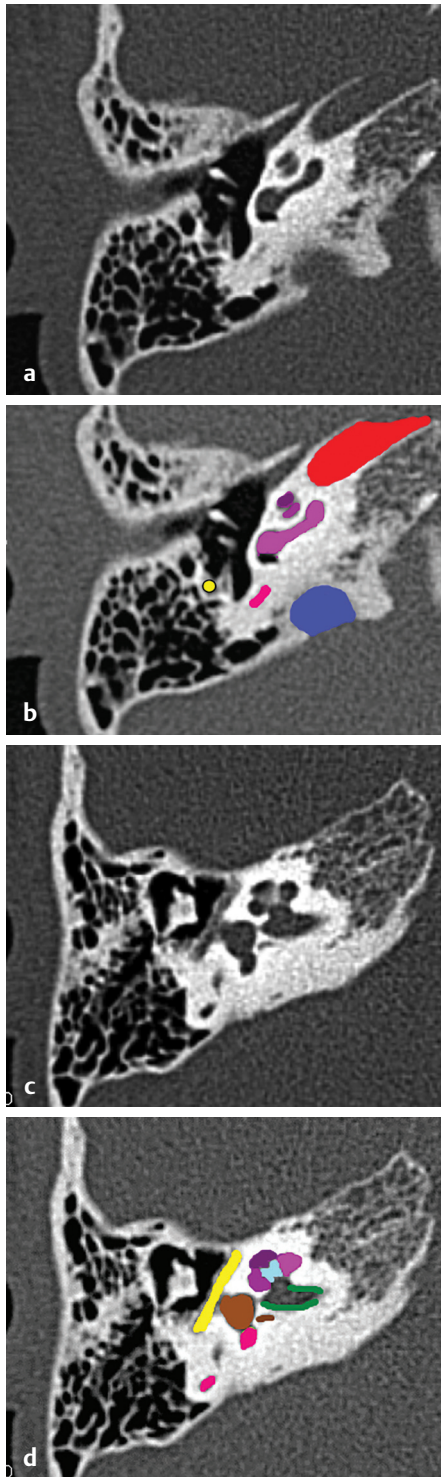


Fig. 4.20 HRCT temporal bone, axial section, bone window show (a, b, c, d) (light blue) modiolus, (purple) apical turn of cochlea, (dark pink) middle turn of cochlea, (pink) posterior SCC, (yellow) tympanic segment of facial nerve, (brown) vestibule and singular canal, (light green) lateral SCC, (dark green) IAC, (Continued)

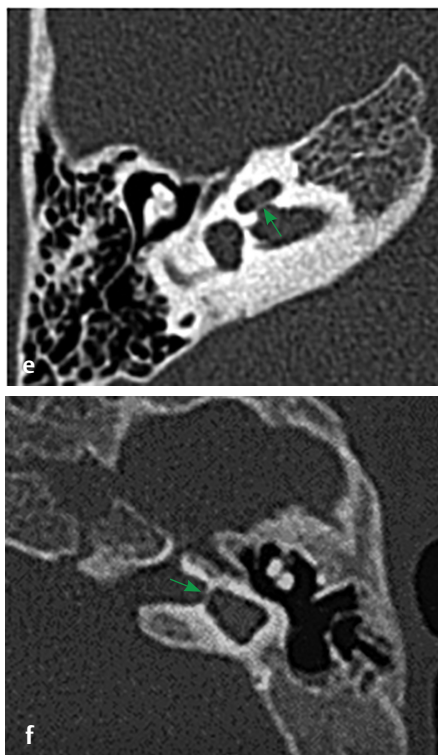


Fig. 4.20 (Continued) **(e)** lamina cribrosa (green arrow) in normal cochlea and **(f)** lamina cribrosa (green arrow in abnormal cochlea).

Table 4.3 SMS classification of cochleovestibular malformations

CVM type	Cochlear morphology	Modiolus	Lamina cribrosa	Others
I	Normal	Normal	Normal	Abnormal
Ila	Abnormal	Complete but smaller	Normal	+/-
Ilb	Abnormal	Partially defective	Normal	+/-
IIIa	Abnormal	Absent	Normal	+/-
IIIb	Abnormal	Absent	Deficient	+/-
IV	Absent	Absent	Absent	+/-

Abbreviations: CVM, cochleovestibular malformations; SMS, Sawai Man Singh.

Inner ear anomalies other than cochlear anomalies, for example an EVA or vestibular dysplasia, were kept in the “others” category. IAC anomalies or cochlear nerve anomalies were dealt with separately, and were therefore not made a part of this classification. **Table 4.3** outlines the details of this classification.

CVM Type I

Features of CVM type I are (Fig. 4.21) as follows:

1. Cochlea is normal.
2. Involves extracochlear parts of the labyrinth like dysplastic vestibule, dysplastic or absent SCCs or EVA.
3. All types of electrodes can be used.
4. Surgery is the same as that for normal cochlea except mild perilymph oozer in EVA.
5. Results are the same as normal cochlea.

CVM Type II

Features of CVM type II are (Fig. 4.22) as follows:

1. Cochlear morphology is not normal.
2. Modiolus is present, however in type IIa the modiolus is complete but smaller and in type IIb it is partially defective in the upper half.
3. The lamina cribrosa is normal so there is no communication between IAC and cochlea.
4. All electrodes can be used.
5. Surgery is the same as that for normal cochlea except mild perilymph oozer in few patients.
6. Results are the same as normal cochlea.

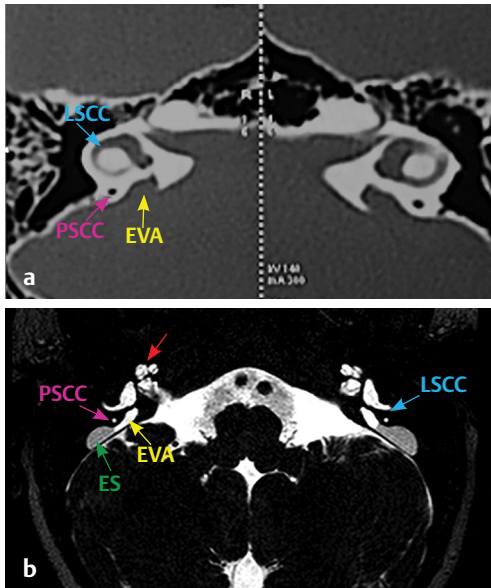


Fig. 4.21 (a) HRCT temporal bone, bone window and (b) MRI CISS sequence, axial sections show SMS CVM type 1 with normal cochlea and EVA (yellow arrow), PSSC (pink arrow), LSCC (blue arrow), and endolymphatic sac (ES, green arrow).

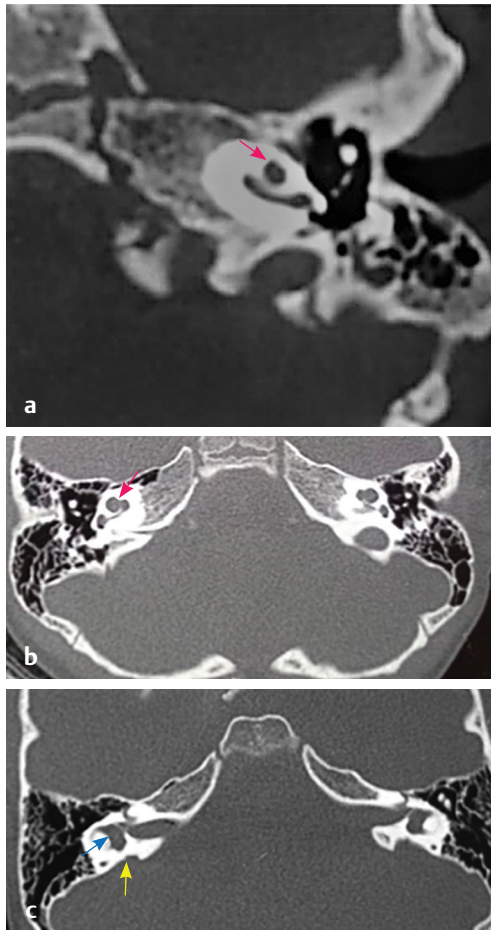


Fig. 4.22 HRCT temporal bone, bone window, axial sections show CVM type II with (a) type IIa and (b, c) type IIb with Mondini dysplasia with cystic apical part of cochlea (pink arrow), dilated vestibule (blue arrow) and EVA (yellow arrow).

CVM Type III

Features of CVM type III are (Fig. 4.23) as follows:

1. Cochlear morphology is not normal.
2. Modiolus is absent.
3. Lamina cribrosa is normal in type IIIa and deficient or absent in type IIIb leading to big communication between IAC and cochlea in latter.
4. As there is no modiolus, the nerve endings are along the periphery of the cochlea. Therefore the best electrodes to be used here would be full banded lateral wall electrodes.
5. Chances of CSF gusher are high in type IIIb, therefore the surgeon should be prepared for dealing with it. Some of the things include: bigger cochleostomy, let the CSF drain out before insertion of electrode array, FORM electrode (proximal part of array having a conical stopper), good sealing of the cochleostomy by tissues, be

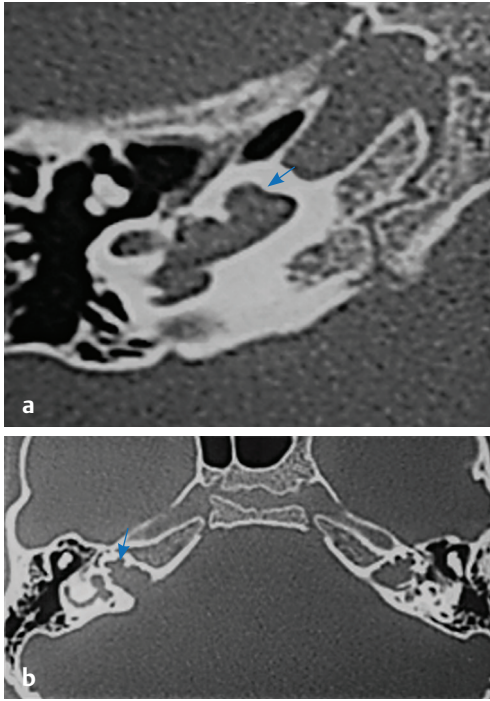


Fig. 4.23 HRCT temporal bone, bone window, axial sections show CVM type III (blue arrow) with (a) type IIIa (absent modiolus, lamina cribrosa present) and (b) type IIIb (absent modiolus and absent lamina cribrosa).

prepared to use tissue glue and lumbar drain and in worst cases subtotal petrosectomy may be needed.

6. Also in type IIIb, due to big communication between cochlea and IAC, there are chances that electrode array may get misplaced into IAC. Therefore, this should be cross-checked intraoperatively with a C-arm. If it is found to be so, then the electrode array should be removed and inserted again in different direction, usually antero-superiorly. Electrode array may also be inserted with help of intraoperative fluoroscopy guidance.

CVM Type IV

Features of CVM type IV are (Fig. 4.24) as follows:

1. Cochlea is absent.
2. Vestibular components may or may not be normally developed.
3. CI is contraindicated and the patient needs an auditory brainstem implant.

The authors find this classification simple and practical, covering all malformation types. This means it can be used universally without any confusion. It can also be utilized to predict outcomes without any overlap of terminologies.

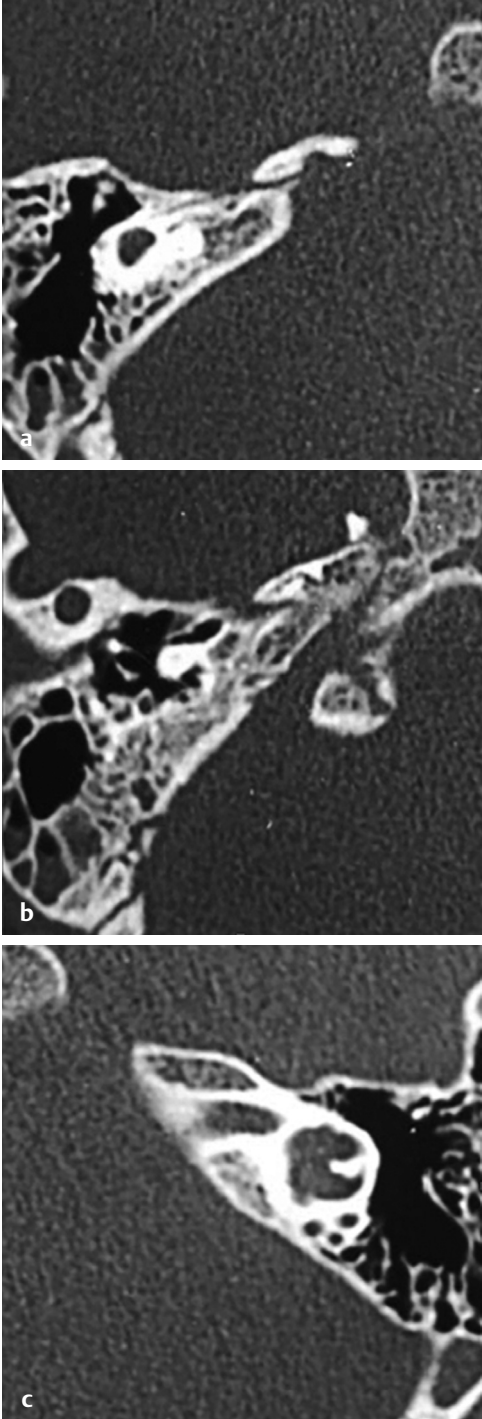


Fig. 4.24 HRCT temporal bone, bone window, axial sections show CVM type IV, **(a)** rudimentary otocyst without IAC, **(b)** CLA, and **(c)** cochlear aplasia.

Cochlear Aperture Anomalies

1. The cochlear aperture is also known as cochlear fossette, or bony cochlear nerve canal (BCNC), that connects the cochlea to the IAC and transmits the cochlear nerve from the cochlea to the IAC (**Fig. 4.25**).
2. Cochlear aperture is clearly visualized in the mid modiolar view and is measured in axial sections of the HRCT temporal bone (**Fig. 4.25**).
3. Cochlear aperture can be normal, hypoplastic, aplastic, or wide.
4. Cochlear aperture aplasia and hypoplasia are most commonly seen with CHARGE association.
5. Cochlear aperture is considered hypoplastic (**Fig. 4.26**) if the width of the BCNC is less than 1.4 mm.²¹
6. Cochlear aperture is considered to be aplastic (**Fig. 4.27**) when the BCNC is completely replaced by bone or there is no canal seen.
7. Cochlear aperture is said to be wide when the width of the BCNC is more than 3 mm. This anomaly is most commonly seen in X-linked progressive hearing loss (SMS CVM type IIIb), wherein the bony partition between the IAC and the cochlea is absent. CI in such cases may be complicated by CSF gusher intraoperatively.
8. Cochlear aperture abnormalities may be accompanied by a narrow or a dilated IAC in most of the cases.

Cochlear Nerve Anomalies

The classification of CVN is of vital importance in the management of inner ear malformations. In MRI CISS/FIESTA sequence, oblique sagittal sections, typically four separate nerves, that is, facial nerve anterosuperior, cochlear nerve (CN) anteroinferior, superior vestibular nerve posterosuperior, and inferior vestibular nerve posteroinferior are clearly distinguished at the fundus of IAC. Casselman et al described cochlear nerve hypoplasia or aplasia based on its dimensions in relation to the ipsilateral facial nerve.²² Studies mention that the CN is of similar size or larger than the facial nerve in 64% of cases and the relative size of the four nerves is symmetrical with the contralateral IAC in 70% of cases.²³ The CN size is correlated with spiral ganglion cell population, and thus may help predict the outcome of cochlear implantation.

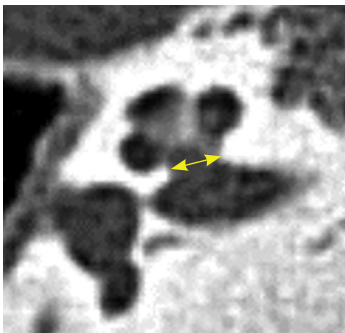


Fig. 4.25 HRCT temporal bone, axial view, bone window shows the measurement of the cochlear aperture (BCNC) at mid-modiolar level.

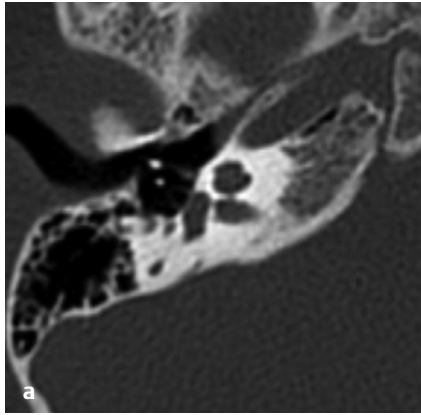


Fig. 4.26 (a) HRCT temporal bone window and (b) MRI CISS sequence, axial sections shows narrow cochlear aperture with hypoplastic cochlear nerve.

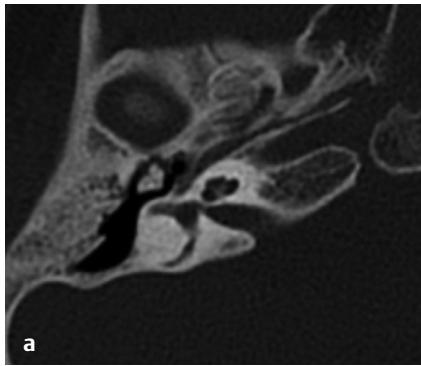
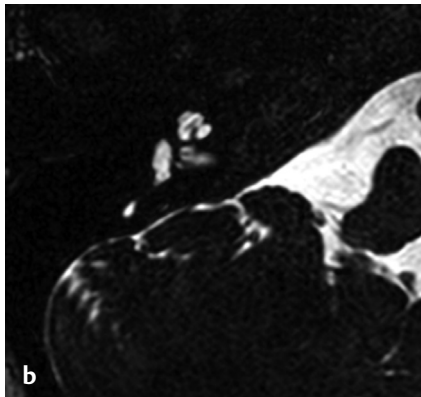
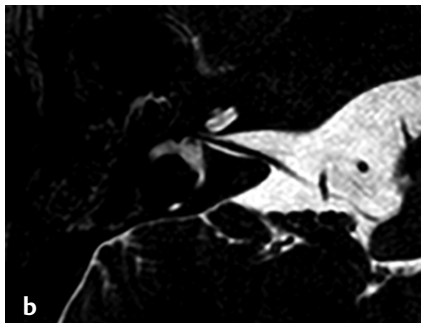

Fig. 4.27 (a) HRCT temporal bone window and (b) MRI CISS sequence, axial sections shows complete cochlear aperture stenosis with cochlear nerve aplasia.



Casselman et al²⁴ came up with a classification in which they divided the CVN anomalies into following types:

- Type I: No CVN seen. Only facial nerve present.
- Type IIa: Absence of CN with dysplastic labyrinth.
- Type IIb: Absence of CN with normal labyrinth.
- Type III: Isolated aplasia of vestibular nerve (never reported till now).

The newer classification by Sennaroglu divides CVN abnormalities into six types.

Normal Cochlear Nerve

1. On oblique sagittal sections, a separate CN is seen in the anteroinferior part of the IAC.
2. The size of CN is similar when compared to the contralateral normal side (**Fig. 4.28**).
3. The size of the CN is similar or slightly larger than the ipsilateral facial nerve sections where we see the CN entering the modiolus of the cochlea (**Fig. 4.28**).

Hypoplastic Cochlear Nerve

1. Separate CN is seen anteroinferiorly.
2. The size of the CN is smaller when compared to the contralateral normal side (**Fig. 4.29**).
3. The size of the CN is smaller than the ipsilateral facial nerve.
4. Most commonly seen in cases with BCNC stenosis or atresia, narrow IAC, and anomalies like CH.

Absent Cochlear Nerve

1. No nerve is seen in the anteroinferior part of the IAC, on MRI oblique sagittal sections (**Fig. 4.30**).
2. Most commonly seen in malformations such as CA, but can occasionally be seen in CH.

Normal Cochleovestibular Nerve

1. A single CVN complex originates at the brainstem and then separates into CN and SVN and inferior vestibular nerves in the IAC (**Fig. 4.31**).
2. In malformations such as a CC, CVN enters the cavity without separating into individual nerves.
3. If the CVN is of size 1.5 to 2 times larger than the ipsilateral facial nerve or similar in size when compared to the contralateral CVN, the CVN is considered normal.

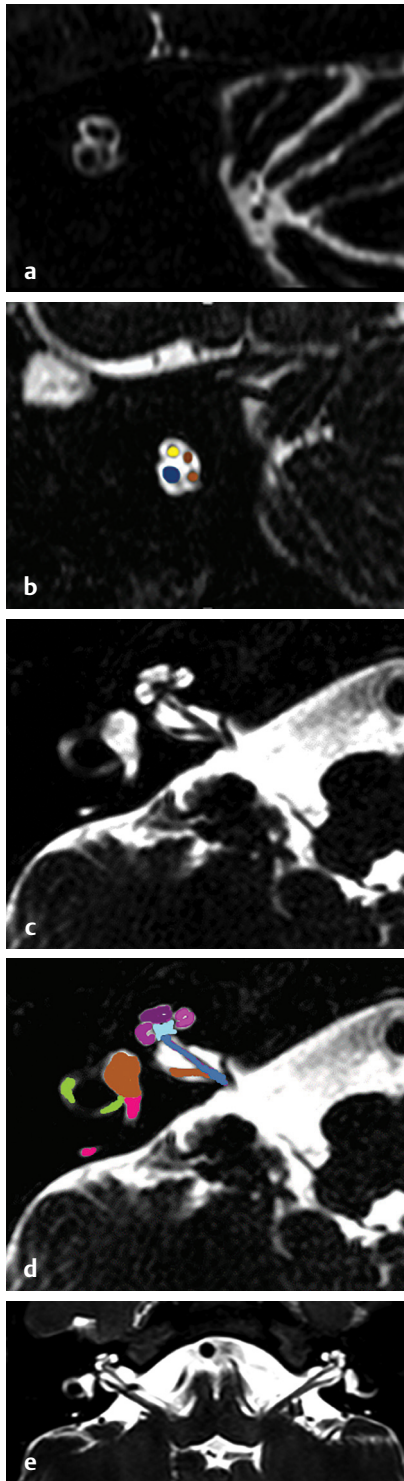


Fig. 4.28 MRI CISS/FIESTA sequence, (a, b) oblique sagittal images at fundus of internal acoustic canal and (c, d, e) axial sections show normal cochlear nerve larger than facial nerve. (Yellow, facial nerve; brown, superior vestibular nerve above and inferior vestibular nerve below; blue, cochlear nerve; Pink - posterior SCC, Purple - apical turn of cochlea, Dark Pink - middle turn of cochlea, Light pink- basal turn of cochlea, Light green - lateral SCC, Light blue - modiolus, and Red arrow shows Rosenthal's canal (RC)).

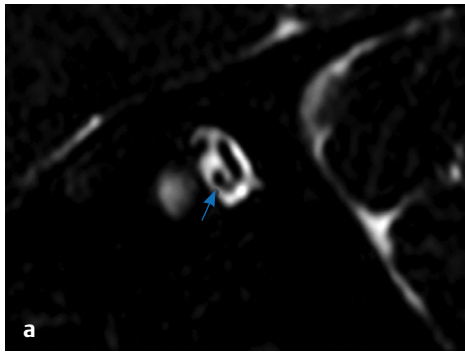


Fig. 4.29 MRI CISS/FIESTA sequence, **(a)** oblique sagittal images at fundus of internal acoustic canal and **(b)** axial sections show hypoplastic cochlear nerve (blue arrow) smaller than the facial nerve.

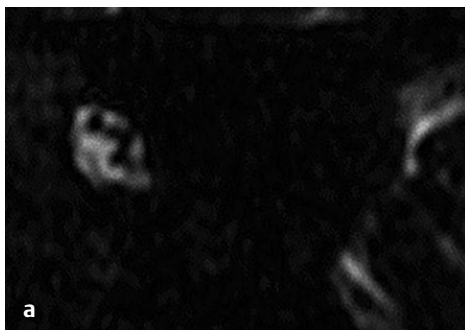
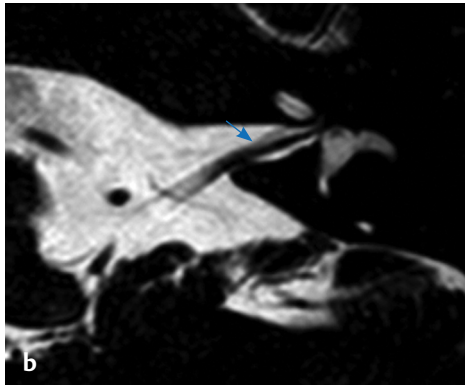
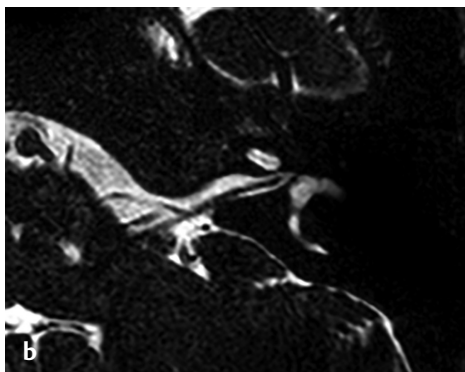


Fig. 4.30 MRI CISS/FIESTA sequence, **(a)** oblique sagittal images at fundus of internal acoustic canal and **(b)** axial sections show absent cochlear nerve.



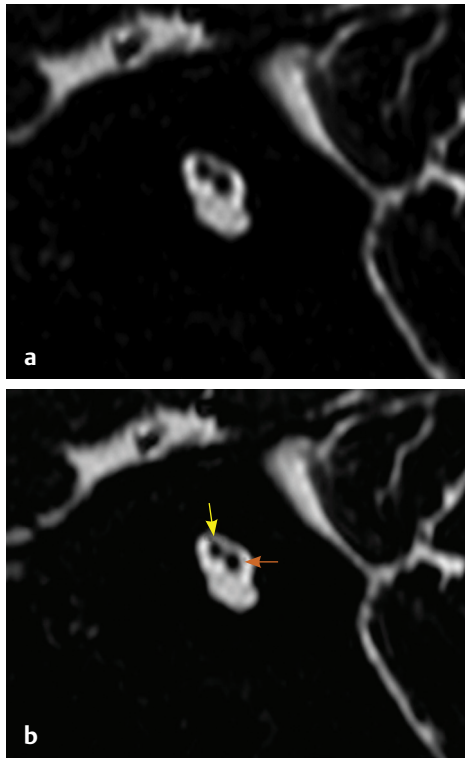


Fig. 4.31 (a) MRI CISS/FIESTA sequence, oblique sagittal images at fundus of internal acoustic canal and (b) show vestibulocochlear nerve (brown arrow) and facial nerve (yellow arrow).

Hypoplastic CVN

1. When CVN is smaller than the contralateral CVN or ipsilateral facial nerve (**Fig. 4.32**).
2. Commonly seen in CC malformations.

Absent CVN

1. CVN is absent (**Fig. 4.33**).
2. Seen in Michel deformity.
3. Only a single nerve, that is, facial nerve can be seen in Michel deformity with absent IAC.

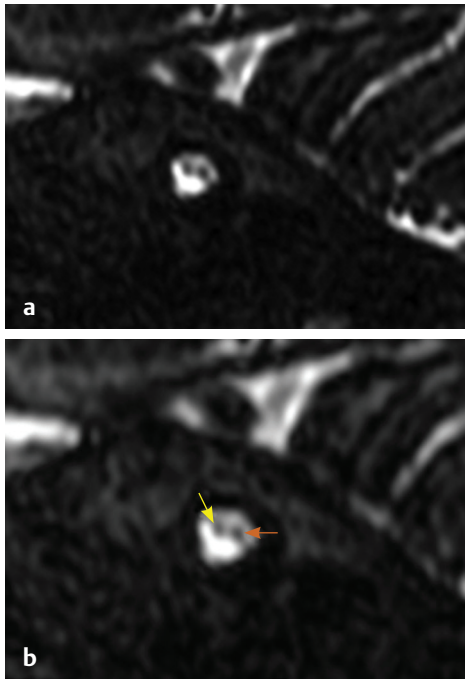


Fig. 4.32 (a) MRI CISS/FIESTA sequence, oblique sagittal reformation images at fundus of internal acoustic canal and (b) show vestibulocochlear nerve (brown arrow) smaller than facial nerve (yellow arrow).

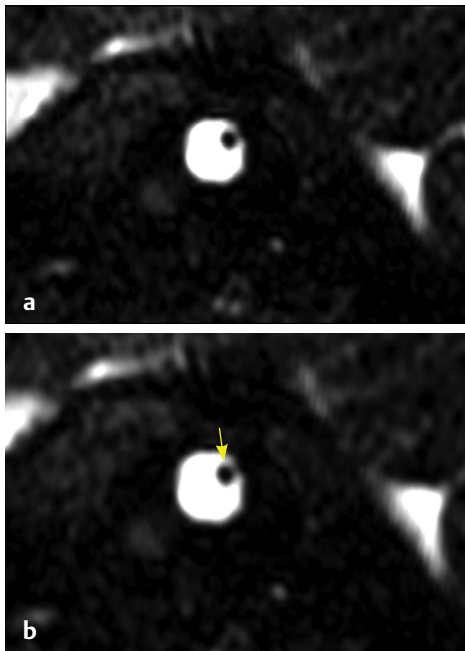


Fig. 4.33 (a) MRI CISS/FIESTA sequence, oblique sagittal images at fundus of IAC and (b) show single facial nerve (yellow arrow).

Internal Acoustic Canal Anomalies

The IAC is a smooth, cylindrical canal that extends from the porus acusticus at the cerebellopontine angle medially to the fundus laterally, adjacent to the inner ear. The IAC transmits the branches of the vestibulocochlear nerves, that is, cochlear nerve, superior and inferior vestibular nerve, singular nerve, and the intracanalicular segment of the facial nerve. Several studies have shown a strong correlation between the width of the IAC and associated CVN anomalies. The normal IAC width is 2 to 8 mm.^{25,26}

The width of the IAC is measured in axial sections of the HRCT temporal bone by drawing a line perpendicular to the long axis of IAC at its mid point (**Fig. 4.34a**). The height and length of the IAC are measured on coronal sections. Height is measured by drawing a line through the mid canal (**Fig. 4.34b**). The upper limit for the height of the IAC is around 8 mm and for the length is generally 10 mm. The normal orientation angle of IAC is 60 to 65°. It is measured by drawing a line anteriorly from an axis drawn along the posterior petrous edge intersecting with a line drawn along the posterior wall of the IAC (**Fig. 4.34c**).²⁶

IAC anomalies are classified into three categories based on the width, length, and duplication. IAC can be narrow or widened based on its width. It could be foreshortened, tortuous, and bulbous based on the height or posteriorly angulated.

Narrow Internal Acoustic Canal

IAC is said to be narrow or stenotic if the width is less than 2 mm (**Figs. 4.35** and **4.36**).^{9,27} Most of the cases IAC stenosis may be accompanied by BCNC stenosis. Several studies have shown the presence of a hypoplastic or aplastic CN associated with a narrow IAC intraoperatively.

Widened Internal Acoustic Canal

IAC is considered to be wide if the width is more than 8 mm. It can be bulbous or fusiform (**Figs. 4.37** and **4.38**). Several syndromes such as CHARGE, Goldenhar, Apert, Patau are frequently associated with widened IAC.²⁸ Bulbous and widened IAC is a classical feature of X-linked mixed hearing loss, in which there is incomplete separation or absence of lamina cribrosa between the IAC and the basal turn of the cochlea, thus increasing the risk of CSF gusher (as in SMS CVM type IIb).

Duplicated Internal Acoustic Canal

It is a very rare congenital anomaly and very few cases have been reported in literature. In this, there is a bony septum that divides IAC into anterosuperior and posteroinferior parts. The anterosuperior portion is usually bigger in size (**Fig. 4.39**).

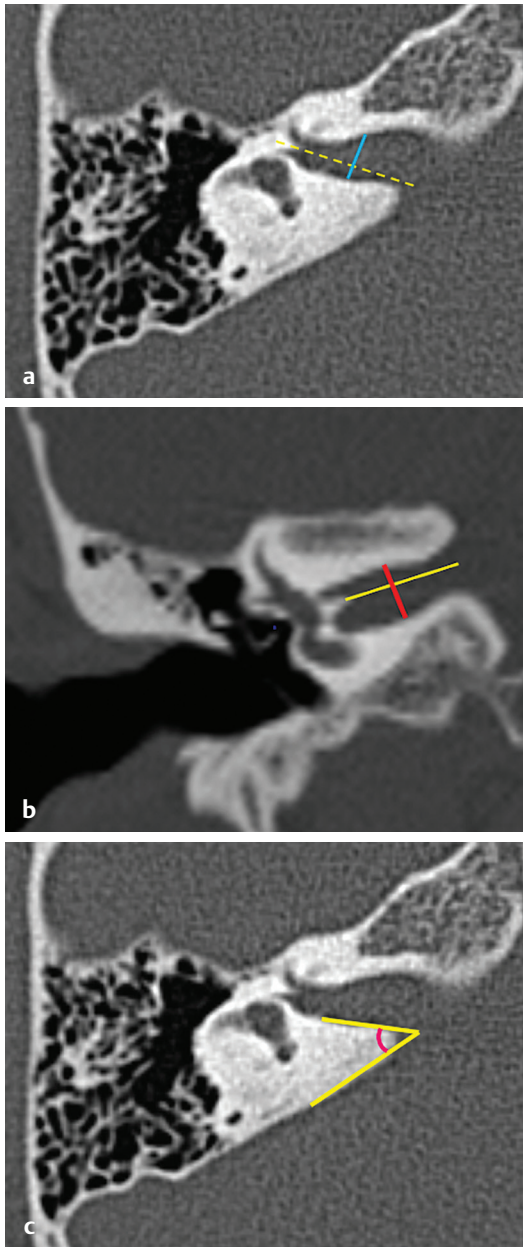


Fig. 4.34 HRCT temporal bone, bone window, **(a)** axial section shows measurement of the width of the internal acoustic canal (IAC) at its midpoint (yellow dotted line, long axis of IAC), **(b)** coronal section showing the measurement of the height of IAC, **(c)** axial section shows measurement of the angle of orientation of IAC.

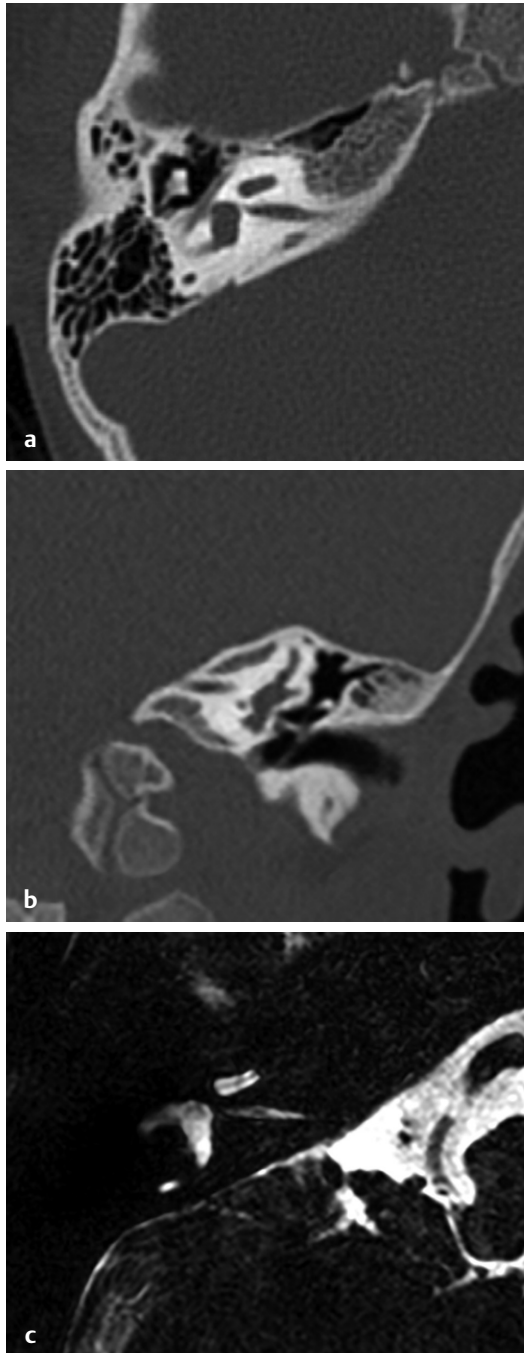


Fig. 4.35 HRCT temporal bone, bone window, **(a)** axial section, **(b)** coronal section, and **(c)** MRI CISS sequence axial section shows narrow internal acoustic canal in normal inner ear.

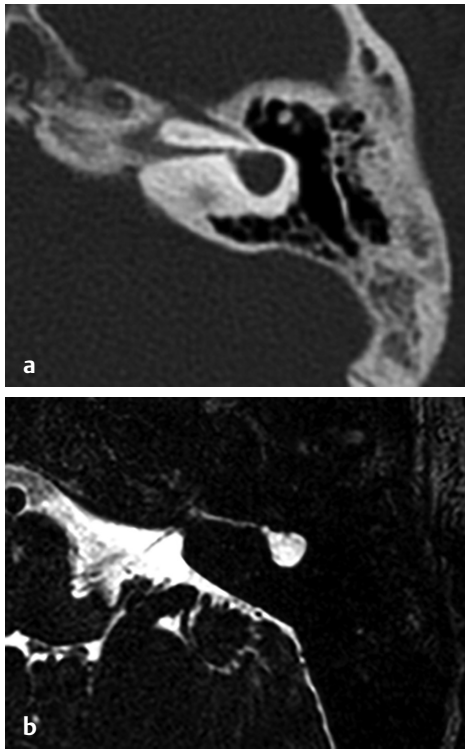


Fig. 4.36 (a) HRCT temporal bone, bone window and (b) MRI CISS sequence axial section shows narrow internal acoustic canal in anomalous inner ear.

Summary of Cochlear Malformations

In order to make these malformations simpler and more practical, authors are trying to describe them by means of some hypothetical diagrams.

Fig. 4.40 explains about normal cochlear anatomy, the important structures like the turns, modioli, interscalar septa, and lamina cribrosa.

Fig. 4.41 talks about the scenario when the cochlea is normal but the rest of the inner ear can be affected (e.g., dysplastic vestibule/SCC/EVA). As the electrode goes only till the initial part of the middle turn, the results do not change and any type of electrode array (full banded/half banded; lateral wall/perimodiolar/midscalar) can be used.

Fig. 4.42 shows the scenario when the modioli are shorter in size or they are defective in the upper half. As the electrode goes only till the initial part of the middle turn, the results do not change and any type of electrode array (full banded/half banded; lateral wall/perimodiolar/midscalar) can be used. This includes IP2 and CH3 (SMS CVM type 2).

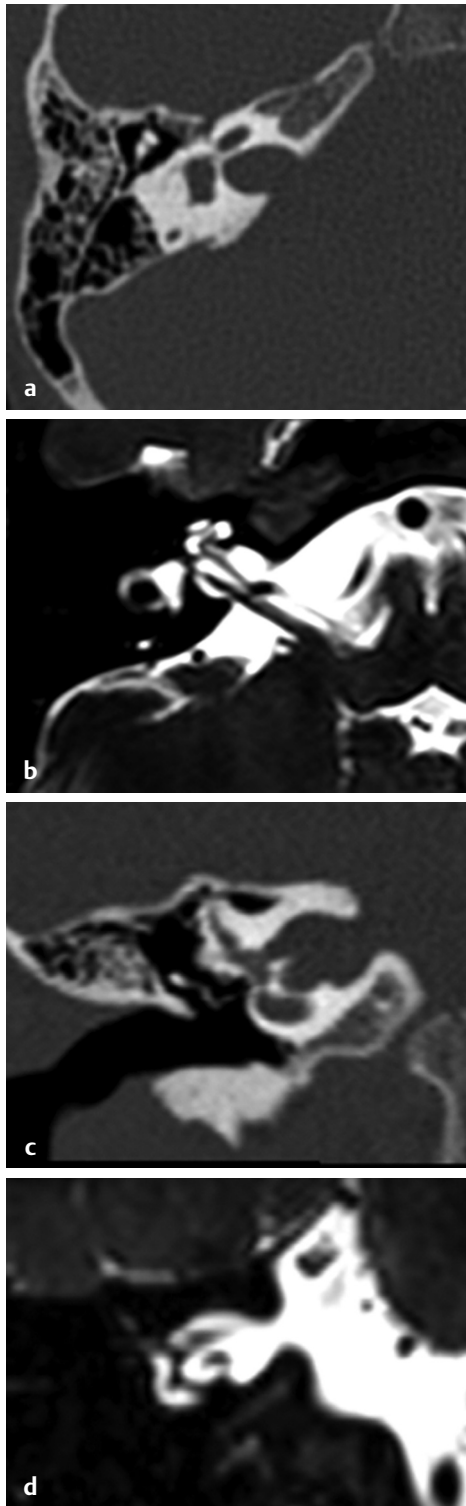


Fig. 4.37 (a, c) HRCT temporal bone, bone window, (a) Axial and (c) coronal sections and (b, d) MRI CISS sequence, (b) axial sections and (d) coronal sections show widened internal acoustic canal with normal inner ear.

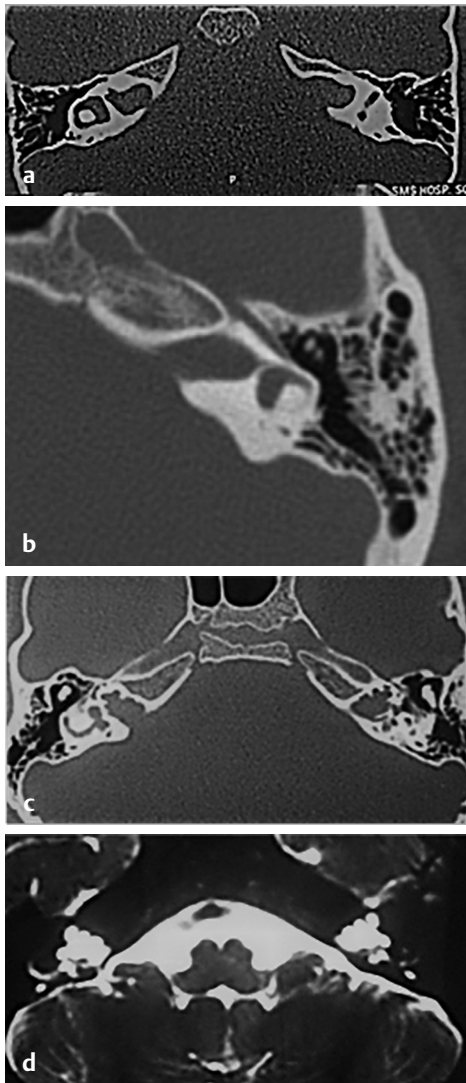


Fig. 4.38 (a, b) HRCT temporal bone, bone window, axial sections show dilated internal acoustic canal (IAC) with cochlear aplasia; and (c) HRCT temporal bone, bone window; and (d) MRI CISS sequence axial sections show widened IAC in SMS CVM type 3.

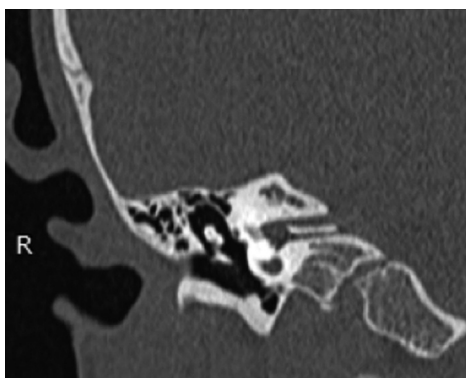

Fig. 4.39 HRCT temporal bone, coronal sections, bone window shows duplicated internal acoustic canal.

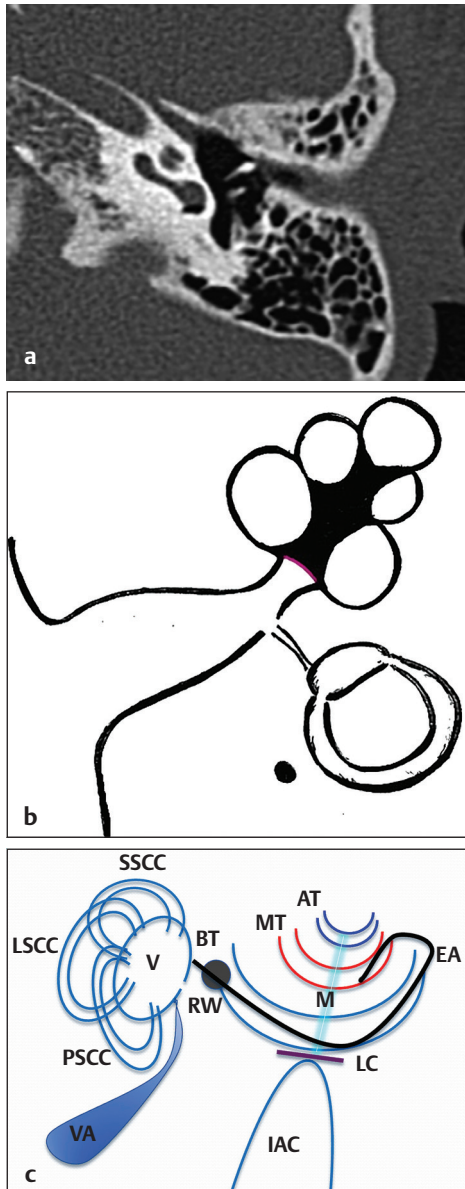


Fig. 4.40 (a) normal radiological anatomy of cochlea, (b) line diagram of normal cochlea, (c) schematic representation of electrode insertion in normal cochlea (going only up to initial part of middle turn) (AT, apical turn; IAC, internal acoustic canal; MT, middle turn; BT, basal turn; M, modiolus; RW, round window; SSCC, superior semicircular canal; LSCC, lateral semicircular canal; PSCC, posterior semicircular canal; EA, electrode array; LC, lamina cribrosa; V, vestibule).

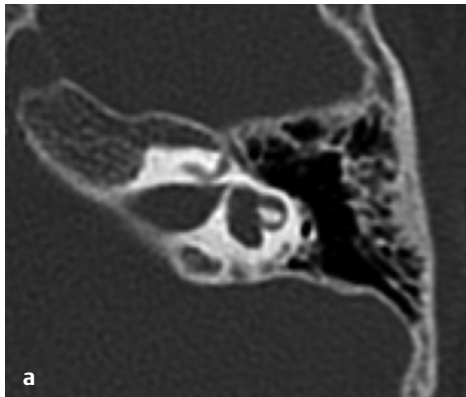
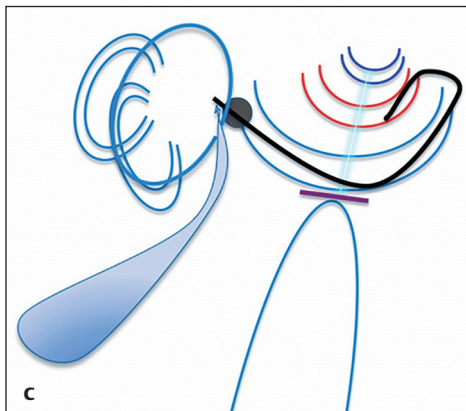


Fig. 4.41 (a) Normal radiological anatomy of cochlea with dilated vestibule, (b) line diagram of normal cochlea with dilated vestibule and EVA, (c) schematic representation of electrode insertion in normal cochlea with dilated vestibule and EVA.



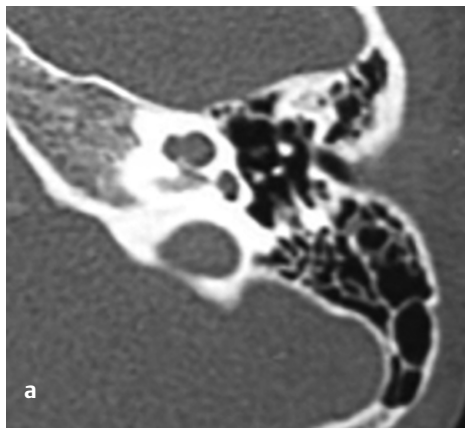


Fig. 4.42 (a) Abnormal radiological anatomy of cochlea with fused apical and middle turns, (b) line diagram of abnormal cochlea with fused middle and apical turns with a defective modiolus, (c) schematic representation of electrode insertion in abnormal cochlea with defective modiolus in the upper half and (d) schematic representation of electrode insertion in abnormal cochlea with shorter modiolus.

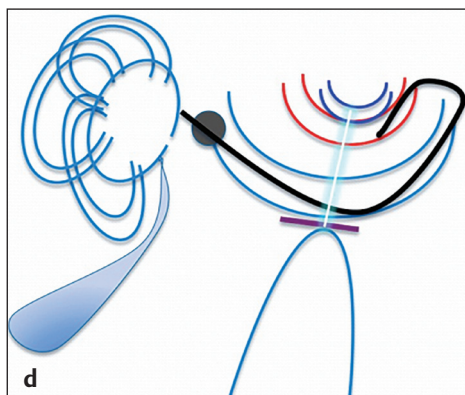
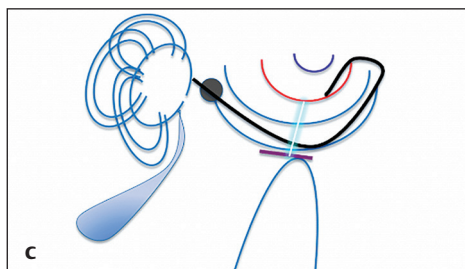
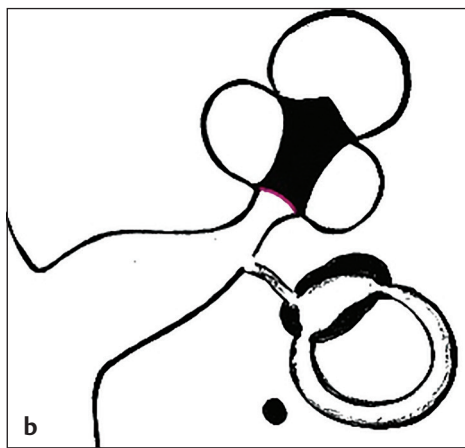


Fig. 4.43 tries to explain the scenario when the modiolus is absent but interscalar septa are intact and lamina cribrosa is absent (IP3 SMS CVM type IIIb). As the modiolus is absent, the nerve endings are present along the periphery of cochlea and therefore half banded/modiolus hugging electrodes should not be used. These electrodes will be facing away from the nerve endings and the precurved electrode array may coil on its own (**Fig. 4.43d**). Full banded lateral wall electrode arrays are best suited for such an anomaly (**Fig. 4.43e**).

Fig. 4.44 shows the scenario when the modiolus and interscalar septa are absent but lamina cribrosa is present (IP1, SMS CVM type IIIa). Just like the last scenario, as the modiolus is absent, the nerve endings are present along the periphery of cochlea and therefore half banded/modiolus hugging electrodes should not be used. These electrodes will be facing away from the nerve endings and the precurved electrode array may coil on its own (**Fig. 4.44d**). Full banded lateral wall electrode arrays are best suited for such an anomaly (**Fig. 4.44e**).

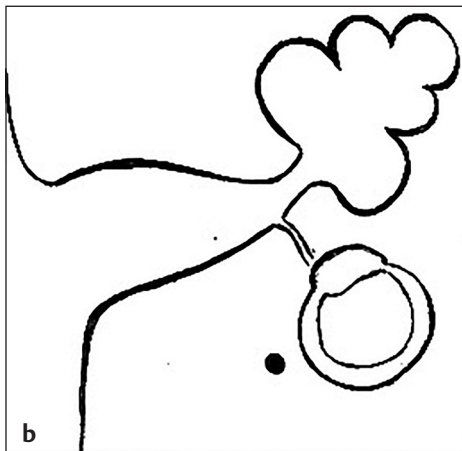
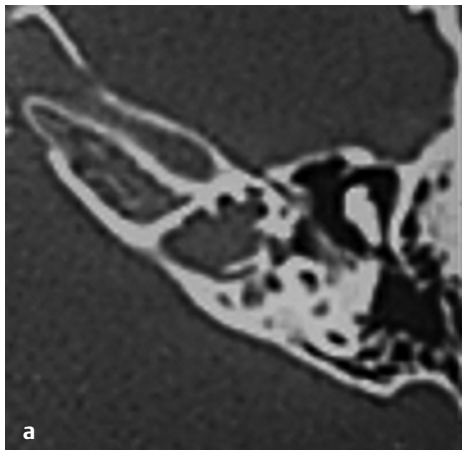


Fig. 4.43 Scenario with abnormal radiological anatomy of cochlea with absent modiolus, absent lamina cribrosa and present interscalar septa, (a) abnormal radiological anatomy, (b) line diagram. (Continued)

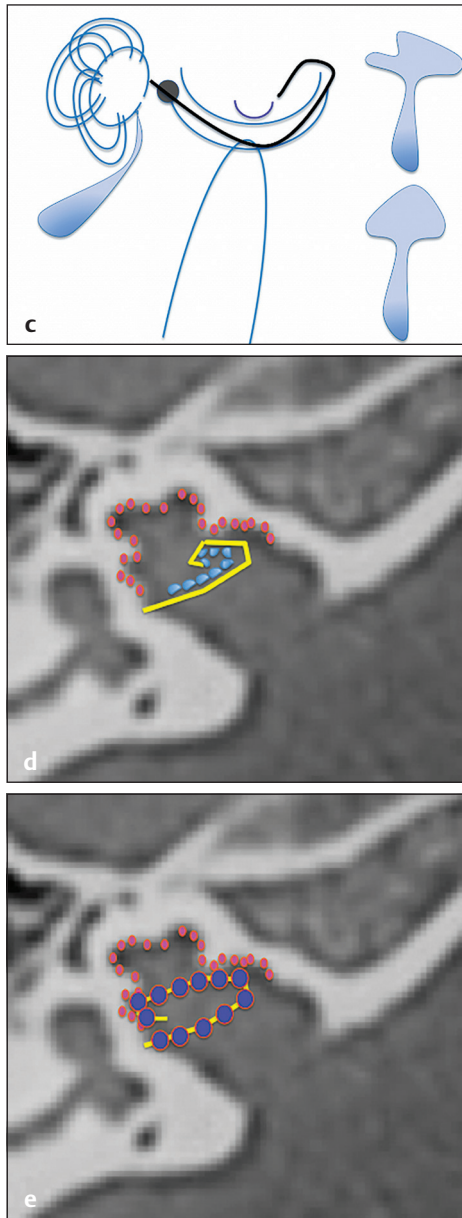


Fig. 4.43 (Continued) **(c)** schematic representation of electrode insertion, **(d)** schematic representation of half banded electrode array (yellow) insertion. Half banded electrode arrays are to be avoided in such cases as electrodes (light blue) are facing away from the nerve endings (pink) and the moduli hugging electrode arrays get coiled upon themselves and **(e)** schematic representation of full banded electrode (yellow) insertion, with electrodes (dark blue) seen in close proximity to neural elements (pink) in the periphery.

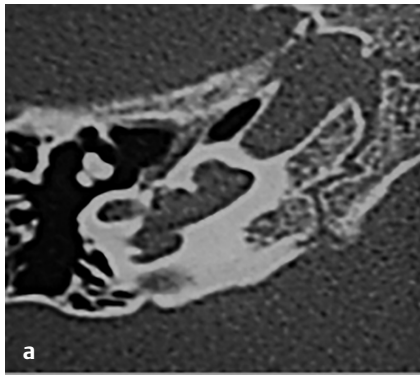
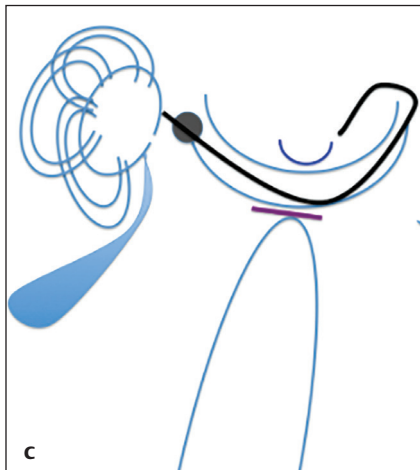
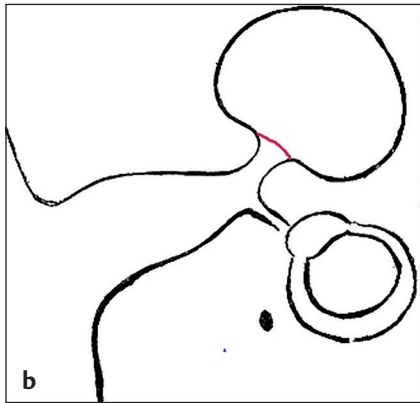


Fig. 4.44 Scenario with abnormal radiological anatomy of cochlea with absent modiolus, lamina cribrosa present and absent interscalar septa, **(a)** abnormal radiological anatomy, **(b)** line diagram, **(c)** schematic representation of electrode insertion. (Continued)



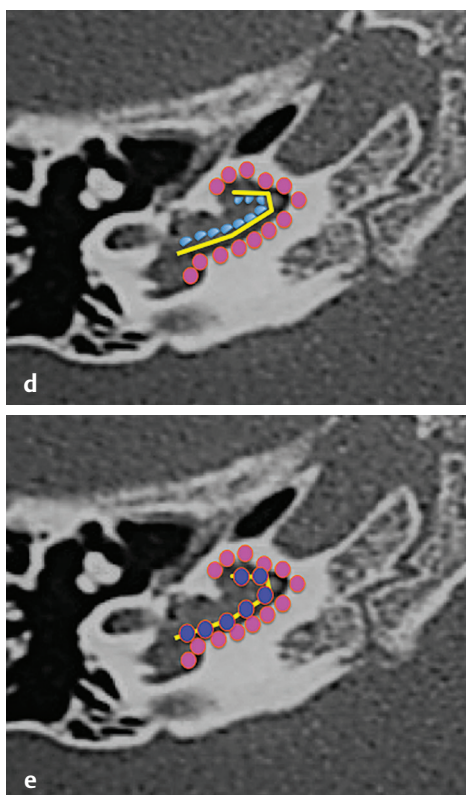


Fig. 4.44 (Continued) **(d)** schematic representation of half banded electrode array (yellow) insertion. Half banded electrode arrays are to be avoided in such cases as electrodes (light blue) are facing away from the nerve endings (pink) and the modulus hugging electrode arrays get coiled upon themselves and **(e)** schematic representation of full banded electrode (yellow) insertion, with electrodes (dark blue) seen in close proximity to neural elements (pink) in the periphery.

References

1. Jackler RK, Luxford WM, House WF. Congenital malformations of the inner ear: a classification based on embryogenesis. *Laryngoscope* 1987; 97(3 Pt 2, Suppl 40)2–14
2. Papsin BC. Cochlear implantation in children with anomalous cochleovestibular anatomy. *Laryngoscope* 2005; 115(1 Pt 2, Suppl 106)1–26
3. Sennaroglu L, Bajin MD. Classification and Current Management of Inner Ear Malformations. *Balkan Med J* 2017;34(5):397–411
4. Mondini C. *Anatomica surdi nati sectio; De Bononiensi scientarum et artium institute atque academia commentarii*. Bononiae. 1971;7:419–431
5. Phelps PD. Cochlear implants for congenital deformities. *J Laryngol Otol* 1992;106(11):967–970
6. Sennaroglu L, Saatci I. A new classification for cochleovestibular malformations. *Laryngoscope* 2002;112(12):2230–2241
7. Grover M, Sharma S, Preetam C, et al. New SMS classification of cochleovestibular malformation and its impact on decision-making. *J Laryngol Otol* 2019;133(5):368–375
8. Sennaroglu L. Histopathology of inner ear malformations: do we have enough evidence to explain pathophysiology? *Cochlear Implants Int* 2016;17(1):3–20
9. Sennaroglu L. Cochlear implantation in inner ear malformations—a review article. *Cochlear Implants Int* 2010;11(1):4–41

10. Monsanto RDC, Sennaroğlu L, Uchiyama M, Sancak IG, Paparella MM, Cureoglu S. Histopathology of inner ear malformations: potential pitfalls for cochlear implantation. *Otol Neurotol* 2019;40(8):e839–e846
11. Sennaroğlu L, Bajin MD. Incomplete partition type III: a rare and difficult cochlear implant surgical indication. *Auris Nasus Larynx* 2018;45(1):26–32
12. Valvassori GE, Clemis JD. The large vestibular aqueduct syndrome. *Laryngoscope* 1978;88(5):723–728
13. Boston M, Halsted M, Meinzen-Derr J, et al. The large vestibular aqueduct: a new definition based on audiologic and computed tomography correlation. *Otolaryngol Head Neck Surg* 2007;136(6):972–977
14. Wilson DF, Hodgson RS, Talbot JM. Endolymphatic sac obliteration for large vestibular aqueduct syndrome. *Am J Otol* 1997;18(1):101–106, discussion 106–107
15. Lo WW, Daniels DL, Chakeres DW, et al. The endolymphatic duct and sac. *AJNR Am J Neuroradiol* 1997;18(5):881–887
16. Sennaroğlu L. Another evidence for pressure transfer mechanism in incomplete partition two anomaly via enlarged vestibular aqueduct. *Cochlear Implants Int* 2018;19(6):355–357
17. Grover M. Enlarged vestibular aqueduct and cochlear anomalies: just an association or a causal relationship? *Cochlear Implants Int* 2019;0(0):1–1
18. Cock E. *A Contribution to the Pathology of Congenital Deafness*. Samuel Highley; 1838
19. McElveen JT Jr, Carrasco VN, Miyamoto RT, Linthicum FH Jr. Cochlear implantation in common cavity malformations using a transmastoid labyrinthotomy approach. *Laryngoscope* 1997;107(8):1032–1036
20. Weiss NM, Langner S, Mlynski R, Roland P, Dhanasingh A. Evaluating common cavity cochlear deformities using CT images and 3D reconstruction. *Laryngoscope* 2021;131(2):386–391.
21. Stjernholm C, Muren C. Dimensions of the cochlear nerve canal: a radioanatomic investigation. *Acta Otolaryngol* 2002;122(1):43–48
22. Casselman JW, Offeciens FE, Govaerts PJ, et al. Aplasia and hypoplasia of the vestibulocochlear nerve: diagnosis with MR imaging. *Radiology* 1997;202(3):773–781
23. Kim HS, Kim DI, Chung IH, Lee WS, Kim KY. Topographical relationship of the facial and vestibulocochlear nerves in the subarachnoid space and internal auditory canal. *AJNR Am J Neuroradiol* 1998;19(6):1155–1161
24. Govaerts PJ, Casselman J, Daemers K, De Beukelaer C, Yperman M, De Ceulaer G. Cochlear implants in aplasia and hypoplasia of the cochleovestibular nerve. *Otol Neurotol* 2003;24(6):887–891
25. Marques SR, Ajzen S, D Ippolito G, Alonso L, Isotani S, Lederman H. Morphometric analysis of the internal auditory canal by computed tomography imaging. *Iran J Radiol* 2012;9(2):71–78
26. Chetcuti K, Kumbla S. The internal acoustic canal—another review area in paediatric sensorineural hearing loss. *Pediatr Radiol* 2016;46(4):562–569
27. Masuda S, Usui S, Matsunaga T. High prevalence of inner-ear and/or internal auditory canal malformations in children with unilateral sensorineural hearing loss. *Int J Pediatr Otorhinolaryngol* 2013;77(2):228–232
28. Bisdas S, Lenarz M, Lenarz T, Becker H. The abnormally dilated internal auditory canal: a non-specific finding or a distinctive pathologic entity. *J Neuroradiol* 2006;33(4):275–277

